ELSEVIER

Interactive CardioVascular and Thoracic Surgery 3 (2004) 575–577

INTERACTIVE CARDIOVASCULAR AND THORACIC SURGERY

www.icvts.org

Case report - Congenital

Double root re-replacement after Ross–Konno operation in a patient with straight back syndrome: clamshell approach

Ersin Erek[a], Yusuf Kenan Yalcinbas[a], Ayse Sarioglu[b], Tayyar Sarioglu[a,*]

[a]*Department of Cardiovascular Surgery, Acibadem Hospital Bakirkoy, Bakirkoy, Istanbul, Turkey*
[b]*Department of Pediatric Cardiology, Acibadem Hospital Bakirkoy, Bakirkoy, Istanbul, Turkey*

Received 15 April 2004; received in revised form 2 June 2004; accepted 7 June 2004

Abstract

The most common indication for reoperation after Ross operation is degeneration of the pulmonic conduit. Pulmonary autograft (aortic root) dilatation and insufficiency is another potential problem during follow-up. This report describes double (aortic and pulmonary) root re-replacement 5 years after Ross–Konno operation in a patient with straight back syndrome. The causes of reoperation were pulmonary conduit degeneration, moderate aortic insufficiency, aortic root dilatation compressing left atrium, left main bronchus and left pulmonary artery. Clamshell technique provided safe and effective approach for this patient with very narrow thoracic cavity.
© 2004 Elsevier B.V. All rights reserved.

Keywords: Ross operation; Pulmonic conduit degeneration; Aortic root dilatation; Straight back syndrome

1. Introduction

Ross–Konno operation is the procedure of choice for pediatric patients with aortic valve disease and annular hipoplasia or tunnel type subaortic obstruction. The main advantages of this technique are growth potential of pulmonary autograft and no need for anticoagulation [1]. Reoperation is rarely needed after Ross operation. The most common indication for reoperation after Ross operation is degeneration of the pulmonic conduit. Pulmonary autograft (aortic root) dilatation and aortic insufficiency is another potential complication affecting long-term results [2,3]. It is known that pulmonary autograft has poor prognosis in patients with connective tissue disorders [4], but there is no report about the results of Ross operation in patients with straight back syndrome. This syndrome is caused by the lack of spine kyphosis and the shortening of the distance between the sternum and thoracic spine leading to compression of the heart. Although prognosis in this syndrome is favourable, some authors suggest that there is high incidence of mitral valve prolapse and bicuspid aortic valve [5]. We report a case with straight back syndrome who underwent Ross–Konno operation 5 years ago. Reoperation was performed due to pulmonary heterograft degeneration, aortic insufficiency and pulmonary autograft dilatation compressing left atrium, left main bronchus and left pulmonary artery.

2. Case report

The patient is a 12 year old boy who had aortic valvotomy due to bicuspid aortic valve stenosis at the age of 3 and underwent Ross–Konno operation at 7 years of age due to aortic stenosis and hypoplastic aortic annulus. Twenty-one millimeter Medtronic Freestyle stentless bioprosthesis was used for right ventricular outflow tract reconstruction. On follow-up he gradually developed shortness of breath and he had two episodes of pulmonary edema that necessitated hospitalization in the last 6 months. On physical examination he was a slender boy. Lack of dorsal kyphosis and the shortening of the distance between the sternum and thoracic spine was prominent. He had 3/6 systolic and diastolic murmur on precordium with increased cardiac activity. Diffuse rales were audible on both the lungs. Telecardiography depicted cardiomegaly and increased bronchovascular markings and calcified

* Corresponding author. Halit Ziya Usakligil Cad. No.1 34140 Bakirkoy, Istanbul, Turkey. Tel.: +90-212-414-4408; fax: +90-212-414-5111.
E-mail address: tsarioglu@asg.com.tr (T. Sarioglu).

1569-9293/$ - see front matter © 2004 Elsevier B.V. All rights reserved.
doi:10.1016/j.icvts.2004.06.009

Downloaded from https://academic.oup.com/icvts/article/3/4/575/677197 by guest on 15 March 2022

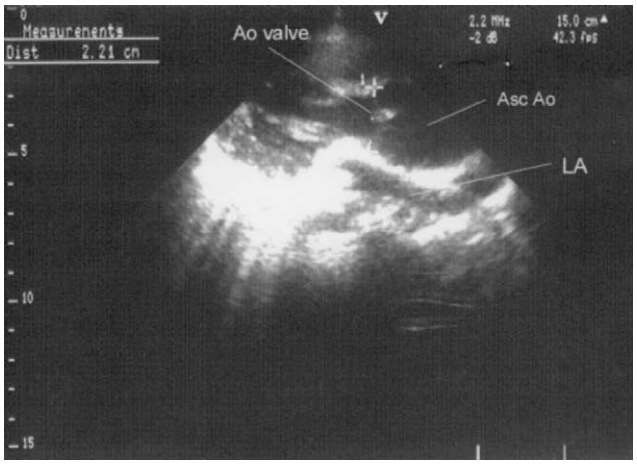

Fig. 1. Echocardiographic examination revealed aortic root dilatation and compressed left atrium behind aortic root. (Asc Ao: Ascending aorta; Ao: Aortic; LA: left atrium).

pulmonary heterograft conduit. Apical part of both lungs had fibrotic appearance, indicating restrictive lung disease. Lateral chest X-ray showed decreased thoracic antero-posterior distance with straight dorsal spine in accordance with straight back syndrome. Echocardiography revealed dilatation of the aortic root (4.5 cm) with moderate regurgitation. Left atrium was compressed behind dilated aortic root (Fig. 1). Moderately stenotic heterograft (right ventricle pressure was 56 mHg) was calcified and degenerated. Computerized tomography and magnetic resonance imaging of thorax confirmed pulmonary autograft dilatation compressing left atrium, left main bronchus and left pulmonary artery. Dilated pulmonary autograft and calcified pulmonic heterograft were tightly stuck to the sternum. Bilateral interstitial pulmonary fibrosis was also noted (Fig. 2).

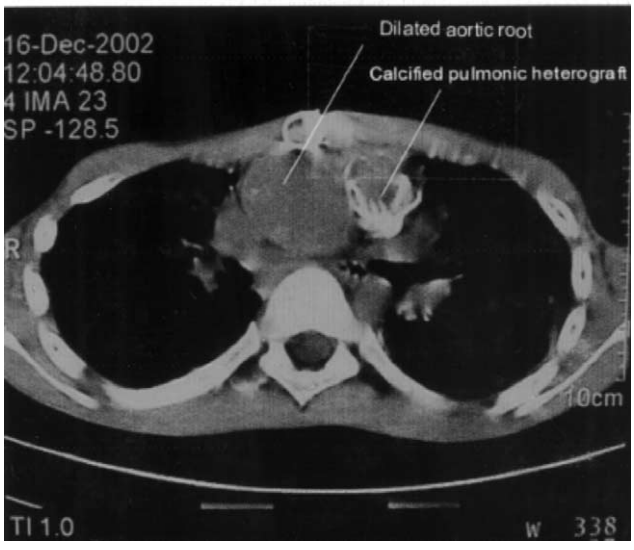

Fig. 2. Computerized CT scan view shows the dilatation of the ascending aorta and heterograft calcification.

The patient underwent reoperation. After anesthetic induction, clamshell approach (bilateral anterior thoracotomy and transvers sternotomy) was preferred for mediastinal re-entry, because of the high risk of injury to the aorta and pulmonary conduit during resternotomy. Dissection of the vital structures was completed without complication. After standard aortic and bicaval cannulation, cardiopulmonary bypass is established. After aortic cross clamp and cardioplegic delivery, aortic aneurysm is resected and Bentall procedure with coronary button reimplantation was performed with 21 mm Medtronic composite graft (Medtronic Hall mechanical valve with dacron tubular graft). Heterograft was resected and replaced with 22 mm Medtronic Contegra bovine jugular vein conduit. Patient came off bypass smoothly.

Postoperative hemodynamic status was stable. Tracheostomy was necessary due to pulmonary fibrosis and restrictive thoracic wall. Patient was discharged on postoperative day 16 in good clinical condition. Pathology report revealed medial myxoid degeneration of the pulmonary autograft.

3. Discussion

Currently Ross–Konno operation is considered as the best surgical option in pediatric patients with aortic stenosis and annular hypoplasia. Although the long-term results are better than other alternatives such as mechanical valve or homograft replacement, reoperations may be rarely necessary due to pulmonary autograft failure and pulmonic conduit degeneration [1,3,4].

Pulmonary conduit degeneration is the most common cause of reoperation after Ross operation. We used Medtronic Freestyle aortic porcine heterograft for this patient as a pulmonic conduit due to scarcity of the homografts in our country. Although early and mid-term results are satisfactory, mild to moderate stenosis with calcification developed in 5 years [3,6].

Pulmonary autograft dilatation may be seen in some patients after Ross operation. This may be the result of structural abnormalities of the native aorta and the pulmonary artery that were observed in patients with bicuspid aortic valves [7] or with connective tissue disorders [4]. Straight back syndrome may be considered a form of connective tissue disorder, but cardiovascular prognosis of this disorder is known to be good [5]. We did not notice any skeletal abnormality during Ross–Konno operation on this patient, but 5 years later, he showed typical radiographic findings of straight back syndrome. We are not sure whether pulmonary autograft dilatation of the patient resulted from this disorder or not. This syndrome complicated the condition of the patient by causing compression to the mediastinal structures of the dilated aortic root due to reduced sternal–spine distance. Apart from this, close

Downloaded from https://academic.oup.com/icvts/article/3/4/575/677197 by guest on 15 March 2022

proximity of the heart and great vessels to the sternum rendered resternotomy very dangerous.

Homografts were not readily available during reoperation, but it was possible to implant an adult sized mechanical valve during reoperation, our choice was Bentall procedure with mechanical valve replacement for aorta, to spare the patient from the risk of further reoperations. For the pulmonary reconstruction, we used heterograft again, because of the known high incidence of mechanical valve related thromboembolic complications on the right side of the heart [8].

In conclusion, clamshell approach provided very safe and effective technique for this difficult reoperation and it can be used for similar cases. Ross operation should be considered very cautiously in patients with straight back syndrome.

References

[1] Calhoon JH, Nolton JWR. Ross/Konno procedure for critical aortic stenosis in infancy. Ann Thorac Surg 1995;60:587–9.

[2] Takkenberg JJ, Zondervan PE, van Herwerden LA. Progressive pulmonary autograft root dilatation and failure after Ross procedure. Ann Thorac Surg 1999;67:551–4.

[3] Sarıoğlu T, Erek E, Yalcinbas YK, Salihoglu E, Sarioglu A, Tekin S. Pericardial collar modification for Ross procedure. Cardiovas Surg 2003;11:229–30.

[4] Elkins RC. Pulmonary autograft. In: Franco KL, Verrier ED, editors. Advanced therapy in cardiac surgery. Hamilton, Ont.: BC Decker; 2003, p. 156.

[5] Ansari A. The straight back syndrome: current perspective more often associated with valvular heart disease than pseudoheart disease: a prospective clinical, electrocardiographic, roentgenographic, and echocardiographic study of 50 patients. Clin Cardiol 1985;8: 290–305.

[6] Erek E, Yalçınbas YK, Salihoğlu E, Öztürk N, Arat S, Sarıoğlu A, Samanlı UB, Sarıoğlu T. Fate of the stentless bioprostheses on the right side of the heart. Asian Thoracic Cardiovasc Surg 2003;11: 58–62.

[7] de SA M, Moshkovitz Y, Butany J, David TE. Histologic abnormalities of the ascending aorta and pulmonary trunk in patients with bicuspid aortic valve disease: clinical relevance to the Ross procedure. J Thorac Cardiovasc Surg 1999;118:588–96.

[8] Nurozler F, Bradley SM. St Jude medical valve in pulmonary position: anticoagulation and thrombosis. Asian Cardiovasc Thorac Ann 2002; 10:181–3.

Downloaded from https://academic.oup.com/icvts/article/3/4/575/677197 by guest on 15 March 2022