CASE REPORT OLGU SUNUMU

DOI: 10.5336/cardiosci.2023-100934

Plastic Bronchitis: A Rare Complication After Fontan Surgery

Fontan Ameliyatı Sonrası Gelişen Nadir Bir Komplikasyon: Plastik Bronşit

Ayla OKTAY[a], Canan AYABAKAN[a], Abdullah DOĞAN[b], Rıza TÜRKÖZ[b], Ayşe SARIOĞLU[a], Tayyar SARIOĞLU[b]

[a]Acıbadem University Faculty of Medicine, Department of Pediatric Cardiology, İstanbul, Türkiye
[b]Acıbadem Bakırköy Hospital, Clinic of Cardiovascular Surgery, İstanbul, Türkiye

This study was presented as an poster presentation at 21st National Congress of Pediatric Cardiology and Pediatric Cardiac Surgery April 27-30, 2023, Muğla, Türkiye.

ABSTRACT Plastic bronchitis (hard, sticky mucous plugs) is a medical emergency where obstructing bronchial casts may cause asphyxia. 9-year-old boy presented with choking cough fits, producing rubbery sputum 1 year after Fontan operation. He had right atrial isomerism, unbalanced complete atrioventricular septal defect, pulmonary atresia, and received bosentan therapy before a fenestrated Fontan operation. Catheterization at presentation revealed oxygen saturation 84%, mean pulmonary artery (PA) pressure 18-19 mmHg, and pulmonary vascular resistance 3.5 WU. Narrow PA segment between the bilateral cavo-pulmonary anastamoses was stented. Medical treatment consisted of intravenous fluconazole, ceftriaxone; oral clarithromycin, prednisolone, sirolimus; inhaler salbutamol, budezonide, pulmozyme, heparin; and middle chain triglyceride diet. There were no casts in the bronchoscopy. One year after his discharge, he is stable, with no recurrences. Elevated PA pressure and failing Fontan circulation needs to be evaluated if plastic bronchitis is seen after Fontan surgery. Urgent medical treatment and bronchoscopy for bronchial casts is very crucial in these patients. Sirolimus may be a new option in medical treatment.

Keywords: Fontan procedure; complications; bronchitis; asphyxia; therapy

ÖZET Plastik bronşit, hava yollarında oluşan sert, yapışkan mukuslu tıkaçlar nedeniyle asfiksiye neden olabilen tıbbi acil durumdur. Dokuz yaşında erkek çocuk Fontan ameliyatından 1 yıl sonra boğulma hissi veren öksürük nöbetleri ve lastik kıvamında yapışkan balgam çıkarma şikâyeti ile başvurdu. Hasta sağ atriyal izomerizm, dengesiz komplet atriyoventriküler septal defekt, pulmoner atrezi nedeniyle yapılan fenestre Fontan ameliyatından önce bosentan tedavisi almıştı. Başvuru anındaki kateterizasyonda oksijen satürasyonu %84, ortalama pulmoner arter (PA) basıncı 18-19 mmHg, pulmoner vasküler direnç 3,5 WU'di. Bilateral kavopulmoner anastamoz arasındaki dar PA segmenti stentlendi. Tıbbi tedavi intravenöz flukonazol, seftriakson; oral klaritromisin, prednizolon, sirolimus; inhaler salbutamol, budezonid, pulmozim, heparin; orta zincirli yağ asidi diyetinden oluşuyordu. Bronkoskopide tıkaç saptanmadı. Hastanın taburculuktan 1 yıl sonra genel durumu iyi ve stabildir, tıkaç oluşumu tekrarlamamıştır. Fontan ameliyatı sonrası gelişen plastik bronşitte yüksek PA basıncı ve Fontan dolaşımı yetersizliği açısından değerlendirme yapılmalıdır. Bronşiyal tıkaçlar için acil tıbbi tedavi ve bronkoskopi çok önemli ve hayat kurtarıcıdır. Sirolimus tedavide yeni bir seçenek olarak değerlendirilebilir.

Anahtar Kelimeler: Fontan işlemi; komplikasyonlar; bronşit; asfiksi; tedavi

Plastic bronchitis (PB) is characterized by the formation of sticky, fibrinous casts in the tracheobronchial branches. This complication can occur in children after Fontan surgery.[1] PB is a medical emergency where these bronchial casts obstruct the respiratory tract, and cause asphyxia.

TO CITE THIS ARTICLE:
Oktay A, Ayabakan C, Doğan A, Türköz R, Sarıoğlu A, Sarıoğlu T. Plastic bronchitis: A rare complication after fontan surgery. Turkiye Klinikleri J Cardiovasc Sci. 2026;37(1):25-9.

Correspondence: Canan AYABAKAN
Acıbadem University Faculty of Medicine, Department of Pediatric Cardiology, İstanbul, Türkiye
E-mail: cayabakan@yahoo.com

Peer review under responsibility of Turkiye Klinikleri Cardiovascular Sciences.

Received: 15 Jan 2024 ***Received in revised form:*** 30 Oct 2024 ***Accepted:*** 26 Feb 2025 ***Available online:*** 12 Mar 2025

2146-9032 / Copyright © 2026 by Türkiye Klinikleri. This is an open access article under the CC BY-NC-ND license (http://creativecommons.org/licenses/by-nc-nd/4.0/).

We present a rare a case of PB after Fontan surgery and discuss its diagnosis and treatment options. The parents of the patient provided informed consent for the anonymous publication of his data.

CASE REPORT

Nine-year-old boy presented with episodes of choking cough, during which he produced long, white, branching, rubbery sputum (Figure 1). He had no fever and showed no respiratory distress between the cough fits. He had been evaluated at a pediatric outpatient clinic and was prescribed oral amoxicillin and inhaler salbutamol.

The patient had a history of right atrial isomerism, unbalanced complete atrioventricular (AV) septal defect, pulmonary atresia and persistent left superior vena cava. He underwent a modified BT shunt operation as a newborn. At 15-months old, he underwent a bilateral bidirectional cavo-pulmonary anastamosis (BCPA), after which he was treated for prolonged chest tube drainage and mediastinitis. At age 5, a major aortopulmonary collateral artery (MAPCA) was embolized with a vascular plug. At age 7, he was evaluated for a Fontan operation. His preoperative pulmonary artery index, mean pulmonary artery (PA) pressure, and pulmonary vascular resistance (PVR) were 200mm^2/m^2, 16mmHg and 3.4 Woods units, respectively. He was prescribed 2mg/kg bosentan (Tracleer TM Johnson and Johnson-Canada) twice daily for high PVR.[2] After 1 year of pulmonary vasodilator therapy his mean PA pressure decreased to 10 mmHg, with an oxygen saturation of 79% and PVR of 1.94 Woods units.

An extracardiac Fontan operation was performed using a 19 mm polytetraflouroethylene (PTFE) tube graft, fenestrated with a 6 mm ringed PTFE graft between the conduit and the right atrium.

Upon presentation, 1 year after the Fontan operation, his heart rate, respiration rate and blood pressure were normal, with an oxygen saturation of 87%. Cardiac examination revealed a single 2nd heart sound and a 2/6 soft pansystolic murmur in the 3rd left intercostal area. Lung auscultation revealed rhonchi in the right middle and basal areas. All other physical examination findings were normal.



FIGURE 1: Bronchial casts expectorated by the patient

TABLE 1: Laboratory results at presention

White blood cell count	16600 cells/mm^3	62% neutrophil 13% monocytes
Hemoglobin	16.2 g/dL	
Thrombocytes	417000 cells/mm^3	
International normalized ratio	1.2	
C-reactive protein	1.83 mg/L	(n<0.79 mg/L)
Procalcitonin	0.047 ng/mL	(n<0.1 ng/mL)
Creatinine	0.46 mg/dL	
Albumin	4.4 g/dL	
ALT	27 IU/L	
AST	29 IU/L	

Table 1 shows the patient's laboratory results, which revealed leukocytosis and mild increase in C-reactive protein. The gram stain of the sputum showed gram negative coccobacilli; it was hypocellular, with few mature squamous cells and alveolar macrophages. Sputum culture reported no pathogenic microorganisms. Serological tests for Adenovirus, In-

fluenza A and B, Aspergillus were negative. Beta D-glucan (fungal) was positive (160 pg/mL). Severe acute respiratory syndrome coronavirus 2 polymerase chain reaction (PCR) and immunoglobulin G were negative. Blood culture remained sterile. Intravenous floconazole (Flukol TM Polifarma-Turkey), ceftriaxone (Cephaxon TM Toprak-Turkey) along with oral clarithromycin (Klamer TM Atabay-Turkey) (used as an anti-inflammatory agent 3 days/week), were administered. Treatment included oral prednisolone (Prednol TM Mustafa Nevzat-Turkey) along with salbutamol (Ventolin TM GlaxoSmithKline-France), budezonide (Cortair TM Vem-Turkey), dornase alpha (Pulmozyme-TM Genentech-USA) and heparin (Nevparin TM Gensenta-Turkey) inhalers to reduce bronchial hyperreactivity and to soften and liquefy the sticky casts. Sirolimus (Rapamune TM Pfizer-Ireland) 1 mg/day and a middle chain triglyceride (MCT) diet were prescribed to reduce lymph production.

Given the respiratory findings were stable, elective bronchoscopy was planned, and the patient was taken to the catheter lab for evaluation of the Fontan circulation. His oxygen saturation, mean PA pressure, Qp/Qs, and Pulmonary Vascular Research Institute were 84%, 18-19 mmHg, 0.98, and 3.5 Woods units, respectively. The fenestration was patent, but left PA segment between the bilateral cavo-pulmonary anastomoses was narrow, so a 2.8cm/8zig Cheatham-Platinum (CP) stent was implanted using a 14X30mm balloon (Figure 2). Sildenafil (Departon TM Abdi İbrahim-Turkey) 1 mg/kg/day 3 times daily was added to the treatment regimen.[3] No casts were observed during the bronchoscopy a week later. The patient was discharged on aspirin, sildenafil, sirolimus, prednisolone and inhalers (salbutamol, budezonide). One year after his discharge, he remains physically and hemodynamically stable, with no recurrence of symptoms.

DISCUSSION

In PB, the patient's cough produces a characteristic sticky, fibrinous sputum containing intrabronchial casts shaped like bronchial branches. The condition may be mistaken for pneumonia due to associated symptoms. The most critical manifestation is the occlusion in the middle and distal airways by casts, which can lead to asphyxia and death.[4] Early recognition of these secretions is crucial for timely diagnosis and intervention in this life-threatening condition.

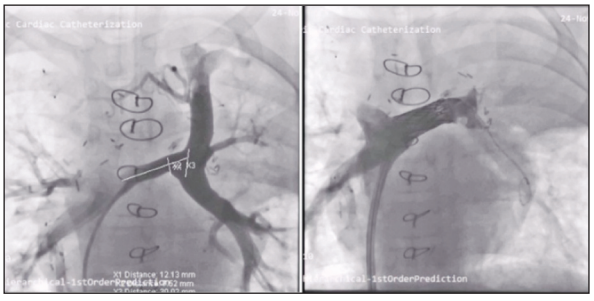

FIGURE 2: Stent implantation in the left pulmonary artery in a patient with Fontan operation

TABLE 2: Heterogeneous etiology of plastic bronchitis

Infectious etiology	Bacterial	Mycoplasma
	Viral	Adenovirus influenza A/B
	Fungal	Aspergillosis
Inflammatory etiology	Asthma	
	Idiopathic chronic eosinophylic pneumonia	
	Primary ciliary dyskinesia	
	Cystic fibrosis	
Abnormal lymph drainage/ obstruction	Congenital anomaly	
	Sickle cell anemia	
	Tumor obstruction	Kaposi sarcoma in HIV infection
		LAP in silicosis
After cardiac operation	Congenital heart disease	Fontan surgery
		Glenn/BCPA
		Operated Fallot tetralogy
		Arterial switch for TGA
	Adult acquired disease	3-vessel bypass for non-ST MI

HIV: Human immunodeficiency virus; LAP: Lymphadenopathy; BCPA: Birectional cavo-pulmonary anastamosis; TGA: Transposition of the great arteries; MI: Myocardial infarction

The heterogeneous etiology of PB is summarized in Table 2. It is more common in adults often related to pulmonary infections, chronic inflammatory processes, or abnormal lymphatic drainage.[5,6] PB is rare in children and is primarily associated with congenital heart defects, mostly following Fontan surgery.[4] The lifetime cumulative incidence of PB after Fontan surgery is up to 4%, most cases occur-

ring within 1-3 years postoperatively. The 5-year mortality rate after diagnosis can be as high as 50%.[7,8]

Pathophysiologically 2 types of casts have been identified: Type 1, contains inflammatory components, is associated with infective/inflammatory etiologies and decreased mucociliary clearance. Type 2, as exhibited in our patient is seen after Fontan surgery, contains acellular proteinaceous lymph material and is associated with inadequate lymphatic drainage.[4]

Treatment depends on the underlying cause, but the primary goal is to remove obstructive casts and prevent the formation of new ones. Urgent bronchoscopy is the mainstay of the treatment, allowing for mechanical removal of obstructive casts and the collection of material for etiological examination. Cryoextraction may be an alternative method.[9] To facilitate cast removal, inhalers containing pulmozyme, heparin, tissue plasminogen activator, or N-acetylcyctein are often administered prior to bronchoscopy.[4] We also prescribed pulmozyme and heparin inhalers to our patient. Even if the etiology is not infectious or inflammatory, oral and/or inhaled steroids, bronchodilators, oral macrolide antibiotics are typically prescribed to suppress secondary bronchial inflammation and decrease cast production. Any accompanying secondary infections should be identified and treated.

In Fontan circulation, chronically elevated systemic venous pressure and non-pulsatile pulmonary flow may lead to lymph stasis, bronchial lymph leakage and cast formation.[1,4] Therefore, any issues with the Fontan circulation that lead to increased systemic venous pressure should be investigated. Our patient already had elevated PA pressure before the Fontan operation, which became favorable only after pulmonary vasodilator therapy and the use of a fenestrated Fontan operation.[2,3] After the Fontan operation, the left PA branch was mildly stenosed, necessitating stenting to ensure unobstructed Fontan circulation. These factors contributed to chronically increased systemic venous pressure, leading to abnormal bronchial drainage.

Prolonged chest-tube drainage after BCPA or Fontan surgery, a history of chylothorax, ascites, and significant aortopulmonary collaterals, as seen in our patient associated with a higher risk of developing PB.[1] In fact, prolonged chest-tube drainage might identify patients with a pathological inflammatory response that may prompt airway cast formation later on.

In persistently symptomatic PB cases, lymphatic system may be evaluated using conventional or magnetic resonance imaging dynamic lymphangiogram to identify congenital or postoperative obstructions in the thoracic duct. In such cases, stenting redirecting lymphatic drainage or embolization, may be effective treatment options.[10-12] Meanwhile an MCT diet or octreotide also reduce chyle production and help control symptoms.

Sirolimus (rapamycin), an mTOR-inhibitor, has recently emerged as a potential treatment for PB. Its use is based on its anti-inflammatory, antiproliferative, and lymphangiogenic properties, which can be particularly beneficial for patients who develop PB after the Fontan operation. Sirolimus, by reducing inflammation, can help decrease the formation of bronchial casts. Additionally, by affecting the growth and permeability of lymphatic vessels, it helps manage underlying lymphatic dysfunction and reduce chyle formation. As an immunosuppressant, it modulates the abnormal immune response that is thought to occur after Fontan surgery.[1,4]

With prompt and aggressive treatment, some patients may experience significant relief from symptoms. However, others may continue to suffer from chronic respiratory issues. Unfortunately, PB tends to be a chronic condition with a risk of recurrence, even after successful initial treatment. PB carries an increased risk of mortality, which can be as high as 50% within 5 years, especially if associated with other complications of Fontan physiology.

In children who have undergone staged Fontan surgery, correct diagnosis of PB and prompt treatment are crutial.

Elevated PA pressure and failing Fontan circulation should be evaluated in all patients to identify and treat correctable issues. Urgent medical treatment bronchoscopy and with a multidisiplinary approach critical.

Acknowledgment

We would like to extend our sincere gratitude to Edward Clark for his invaluable assistance in reviewing and editing the language of this manuscript.

Source of Finance

During this study, no financial or spiritual support was received neither from any pharmaceutical company that has a direct connection with the research subject, nor from a company that provides or produces medical instruments and materials which may negatively affect the evaluation process of this study.

Conflict of Interest

No conflicts of interest between the authors and / or family members of the scientific and medical committee members or members of the potential conflicts of interest, counseling, expertise, working conditions, share holding and similar situations in any firm.

Authorship Contributions

Idea/Concept: *Canan Ayabakan, Ayla Oktay;* ***Design:*** *Ayla Oktay, Canan Ayabakan, Abdullah Doğan, Rıza Türköz;* ***Control/Supervision:*** *Canan Ayabakan;* ***Data Collection and/or Processing:*** *Ayla Oktay, Abdullah Doğan;* ***Analysis and/or Interpretation:*** *Canan Ayabakan, Rıza Türköz;* ***Literature Review:*** *Ayla Oktay;* ***Writing the Article:*** *Canan Ayabakan, Ayla Oktay;* ***Critical Review:*** *Ayşe Sarıoğlu, Tayyar Sarıoğlu, Rıza Türköz;* ***Materials:*** *Abdullah Doğan, Ayla Oktay.*

REFERENCES

1. Schumacher KR, Singh TP, Kuebler J, Aprile K, O'Brien M, Blume ED. Risk factors and outcome of Fontan-associated plastic bronchitis: a case-control study. J Am Heart Assoc. 2014;3(2):e000865. [Crossref] [PubMed] [PMC]
2. Jeremiasen I, Tran-Lundmark K, Idris N, Tran PK, Moledina S. Pulmonary vasodilator therapy in children with single ventricle physiology: effects on saturation and pulmonary arterial pressure. Pediatr Cardiol. 2020;41(8):1651-9. [Crossref] [PubMed] [PMC]
3. Mori H, Park IS, Yamagishi H, Nakamura M, Ishikawa S, Takigiku K, et al. Sildenafil reduces pulmonary vascular resistance in single ventricular physiology. Int J Cardiol. 2016;221:122-7. [PubMed]
4. Patel N, Patel M, Inja R, Krvavac A, Lechner AJ. Plastic bronchitis in adult and pediatric patients: a review of its presentation, diagnosis, and treatment. Mo Med. 2021;118(4):363-73. [PubMed] [PMC]
5. Shah A, Donovan J, Marino P, Shah PL, Devaraj A, Wechalekar K, et al. A lesson in plasticity: a 74-year-old man with plastic bronchitis. Thorax. 2017;72(11):1055-7. [Crossref] [PubMed]
6. Coen M, Daniel L, Serratrice J. An adult case of plastic bronchitis: a rare and multifactorial disease. J Thorac Dis. 2018;10(1):E16-E19. [PubMed] [PMC]
7. Caruthers RL, Kempa M, Loo A, Gulbransen E, Kelly E, Erickson SR, et al. Demographic characteristics and estimated prevalence of Fontan-associated plastic bronchitis. Pediatr Cardiol. 2013;34(2):256-61. [Crossref] [PubMed] [PMC]
8. Larue M, Gossett JG, Stewart RD, Backer CL, Mavroudis C, et al. Plastic bronchitis in patients with fontan physiology: review of the literature and preliminary experience with fontan conversion and cardiac transplantation. World J Pediatr Congenit Heart Surg. 2012;3(3):364-72. [PubMed]
9. Sriratanaviriyakul N, Lam F, Morrissey BM, Stollenwerk N, Schivo M, Yoneda KY. Safety and clinical utility of flexible bronchoscopic cryoextraction in patients with non-neoplasm tracheobronchial obstruction: a retrospective chart review. J Bronchology Interv Pulmonol. 2015;22(4):288-93. [Crossref] [PubMed]
10. Languepin J, Scheinmann P, Mahut B, Le Bourgeois M, Jaubert F, Brunelle F, et al. Bronchial casts in children with cardiopathies: the role of pulmonary lymphatic abnormalities. Pediatr Pulmonol. 1999;28(5):329-36. [PubMed]
11. Parikh K, Witte MH, Samson R, Teodori M, Carpenter JB, Lowe MC, et al. Successful treatment of plastic bronchitis with low fat diet and subsequent thoracic duct ligation in child with fontan physiology. Lymphology. 2012;45(2):47-52. [PubMed]
12. Shah SS, Drinkwater DC, Christian KG. Plastic bronchitis: is thoracic duct ligation a real surgical option? Ann Thorac Surg. 2006;81(6):2281-3. [Crossref] [PubMed]