ENDOCRINOLOGY RESEARCH AND PRACTICE

SOCIETY OF ENDOCRINOLOGY AND METABOLISM OF TURKEY

CASE REPORT
Endocrinol Res Pract. 2024;28(1):53-55

Adrenocorticotropic Hormone-Producing Pheochromocytoma in a Patient with Adrenal Incidentaloma

ABSTRACT

Pheochromocytomas are challenging and life-threatening neoplasms. They can secrete a great variety of hormones and peptides apart from catecholamines. A case of adrenocorticotropic hormone (ACTH)-secreting adrenal pheochromocytoma, which caused Cushing's syndrome, is presented herein. A 60-year-old female was referred for an adrenal mass evaluation. It was detected incidentally during the assessment of her back and abdominal pain. She suffered from high blood pressure for 30 years and diabetes mellitus for 15 years. The computerized abdominal tomography showed a 46 × 35 mm cystic necrotic mass on the right side at 17-20 Hounsfield units, consistent with a non-adenomatous lesion. Laboratory analysis identified elevated levels of catecholamine and hypercortisolism. She underwent an adrenalectomy. Histological features were characteristic of pheochromocytoma. Immunostaining also confirmed the tumor was expressing ACTH. A diagnosis of ACTH-producing pheochromocytoma was made. The catecholamine metabolites were normal post adrenalectomy. Two months after the surgery, we assessed her for hypercortisolism. The dexamethasone suppression test was negative for endogenous hypercortisolism. This is a very rare cause of ectopic Cushing syndrome due to incidentally detected pheochromocytoma.

Keywords: Mixed corticomedullary tumor, adrenal, pheochromocytoma, ectopic ACTH, adrenal incidentaloma

Introduction

Pheochromocytomas originate from chromaffin cells of the adrenal medulla. They are rare tumors, with a yearly estimated incidence of 4-8 per 1 000 000 person-years.[1,2] Pheochromocytomas may be challenging and life-threatening neoplasms. They are frequently associated with various clinical courses. They are heterogeneous tumors, and they can secrete a wide variety of hormones and peptides apart from catecholamines; interleukins, calcitonin, adrenocorticotropic hormone (ACTH), and corticotropic hormone (CRH).[3-8] Although the classic symptoms are episodic headache, diaphoresis, hypertension, and tachycardia, clinical features can be extremely different, mimicking the differentiation of the cells, and the diagnosis can be challenging.[9] About 10% of patients with pheochromocytomas may present with an adrenal incidentaloma, and these tumors can be silent.[10] Adrenocorticotropic hormone seems to be the most common co-secreted hormone.[11]

We report a case of ACTH-secreting adrenal pheochromocytoma, which caused Cushing's syndrome, that was found incidentally. Informed consent was obtained from the patient.

Case Presentation

A 60-year-old woman was referred to our endocrinology clinic for evaluating her adrenal incidentaloma which was detected during the search of her lower back and abdominal pain. She had a history of high blood pressure for 30 years and diabetes mellitus for 15 years. Thyroidectomy was made for multinodular goiter 25 years ago. She went through invasive procedures for her cranial aneurysm 1.5 years ago. She used amlodipine at 10 mg, metoprolol at 25 mg, doxazosin at 4 mg, lisinopril at 20 mg, diphenylhydantoin at 2 × 100 mg, and metformin at 2 × 1000 mg. After a physical examination, her blood pressure was 170/100 mmHg, and her body mass index was 25.9 kg/m^2. Approximately 1 × 1 cm thyroid node was palpated on the right side of her thyroid.

İnan Anaforoğlu[1]

Ayten Livaoğlu[2]

Ekrem Algün[3]

[1]*Department of Endocrinology and Metabolism, Mehmet Ali Aydınlar Acıbadem University Faculty of Medicine, İstanbul, Turkey*
[2]*Department of Pathology, Trabzon Kanuni Education and Research Hospital, Trabzon, Turkey*
[3]*Giresun Ada Hospital, Endocrinology Clinic, Giresun, Turkey*

Corresponding author:
İnan Anaforoğlu
✉ ianaforoglu@hotmail.com

Received: May 3, 2023
Accepted: October 3, 2023
Publication Date: January 2, 2024

Cite this article as: Anaforoğlu İ, Livaoğlu A, Algün E. Adrenocorticotropic Hormone-producing pheochromocytoma in a patient with an adrenal incidentaloma. *Endocrinol Res Pract.* 2024;28(1):53-55.

DOI: 10.5152/erp.2024.22010

Copyright @ Author(s) – Available online at http://endocrinolrespract.org
This journal is licensed under a Creative Commons (CC BY-NC-SA) 4.0 International License.

She was lacking headache, palpitations, diaphoresis, buffalo hump, easy bruisability, weight gain, plethora, moon face, striae, and hirsutism. To evaluate the adrenal mass, an abdominal computerized tomography was performed; it showed a 46 × 35 mm, right-sided, cystic-necrotic mass at 17-20 Hounsfield units (HU) consistent with a non-adenomatous lesion (Figure 1). A full-thorough evaluation of the adrenal medulla and cortex functions was made to see the functional status of the incidentaloma. Plasma aldosterone and renin activity were measured to evaluate a possible mineralocorticoid excess. They were found to be normal, and their ratio was normal. Her sodium and potassium levels were also normal. Laboratory studies resulted in high levels of catecholamines and endogenous hypercortisolism. Metanephrine and normetanephrine were measured twice: metanephrine was 1300.8-2065.5 µg/24 hours (reference range: 52-341 µg/24 hours) and normetanephrine was 484.8-792 (reference range: 88-444 µg/24 hours). Midnight cortisol was 18.6 µg/dL; after the Liddle test, cortisol was 19.2 µg/dL; 24-hour urinary cortisol level was 576 nmol/L; ACTH was measured twice: 20.5-53.2 pg/mL.

As ACTH was found to be high, a diagnosis of ACTH-dependent hypercortisolemia was made, but pituitary MRI was normal. She was prepared for the surgery with the maximum doses of alpha blockage followed by beta blockage until her blood pressure and heart rate were checked. An assessment was made to search for possible medullary thyroid carcinoma, and the calcitonin level was detected as normal (<2; 0-0.12 pg/mL). A biopsy performed after adrenalectomy to avoid a possible pheochromocytoma crisis that might be triggered by the invasive procedure revealed a benign result of fine needle aspiration of the thyroid nodule. She was given an operation adrenalectomy for the excess of catecholamines to prevent an adrenal crisis. She was operated on laparoscopically. Macroscopically, the mass was 4 cm, grey and brown, containing cystic and hemorrhagic fields. Histological features were typical of pheochromocytomas.

The tumor expressed synaptophysin, chromogranin, neuron-specific enolase, and weak-local expression of vimentin, as well as inhibin, HMB-45, and melan-A by immunohistochemistry. S-100 expression was present in sustentacular cells. Immunostaining was done for ACTH, confirming that the tumor expressed ACTH. The distribution of ACTH staining was not widespread; there were focal, small, neoplastic cell groups staining ACTH (Figure 2). Ki-67 positivity was 1%-2%, and staining by p53 was very weak. The pass score was 6. A diagnosis of an ACTH-producing pheochromocytoma was made.

MAIN POINTS

- The clinical spectrum of adrenocorticotropic hormone-secreting pheochromocytomas may vary from asymptomatic cases to fatal cases.
- Pheochromocytomas are heterogeneous tumors associated with different and unexpected clinical courses, as they can produce a great variety of hormones and peptides beyond catecholamines.
- Adrenocorticotropic hormone seems to be the most common co-secreted hormone.

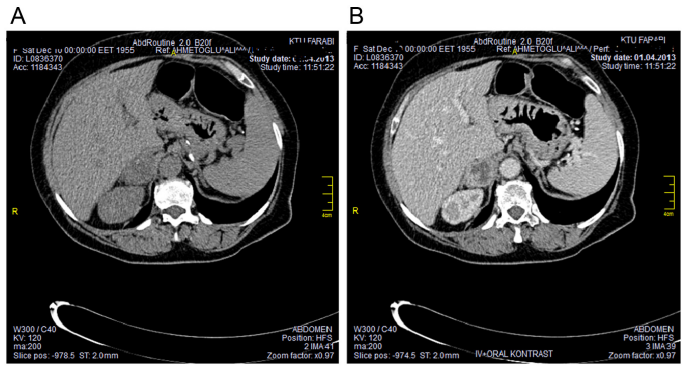

Figure 1. (A) Computerized tomography image of the adrenal gland demonstrating a right-sided 46 × 35 mm large adrenal tumor at 17-20 Hounsfield units (HU). (B) Computerized tomography with contrast demonstrating a cystic necrotic mass compatible with a non-adenomatous lesion.

Catecholamine metabolites were measured, and they were at normal ranges after adrenalectomy; metanephrine: 49.3-88.3 µg/24 hours (52-341 µg/24 hours), normetanephrine: 272.4-176.6 µg/24 hours (88-444 µg/24 hours).

She was evaluated 2 months after the operation to see if hypercortisolism was still present. The dexamethasone suppression test was suppressed.

Discussion

This case represents a very rare cause of ectopic Cushing's syndrome due to a pheochromocytoma detected incidentally. After resection of the adrenal mass, endogenous hypercortisolemia and catecholamine metabolites excesses were resolved.

Ectopic Cushing's syndrome is a rare condition usually accompanied by bronchial carcinoid, small cell lung cancer, or medullary thyroid carcinoma.[11] Ectopic ACTH secretion from a pheochromocytoma was defined as early as 1955 by Roux et al.[12] After Forman et al[13] defined the diagnostic criteria in 1979, Chen et al[14] revised the criteria as having clinical and laboratory evidence of hypercortisolism accompanying increased levels of ACTH; proven pheochromocytoma with

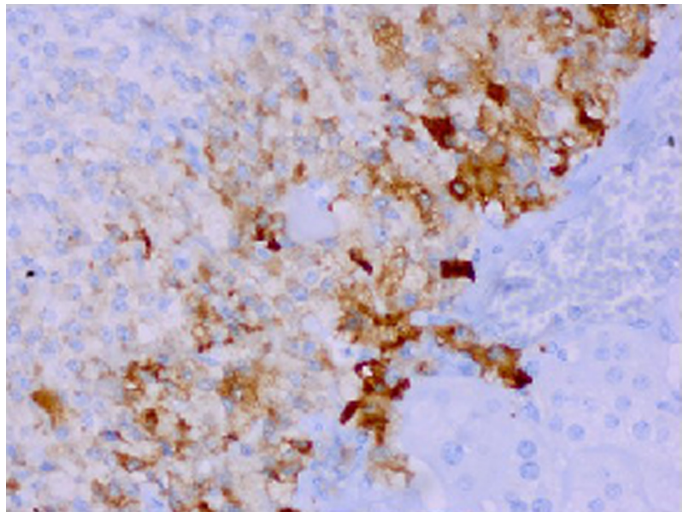

Figure 2. Positive staining for adrenocorticotropic hormone.

elevated levels of urinary catecholamines or adrenal mass on MRI; disappearing signs and symptoms related to catecholamine excess; and rapid normalization of ACTH levels following adrenalectomy. Our case met all these criteria. Causality could not be demonstrated between these 2 entities, arising from different parts of the adrenal gland. Recently, Cheng et al[15] described 3 cases of ectopic ACTH-secreting pheochromocytomas; they showed adrenal medullary hyperplasia in their biopsy specimens and concluded that the adrenal medulla could be a site for ectopic secretion of ACTH. Falhammar et al[8] reported the first medullary hyperplasia case in 2017 and concluded that medullary hyperplasia can be accepted as a precursor of pheochromocytoma. Cheng et al[15] pointed to the presence of a possible local, intra-adrenal CRH/ACTH system, and adrenal medullary cells may have the potential to posse ACTH into plasma. Although Forman et al[13] and Chen et al[14] noted that negative immunostaining of ACTH on tumor tissue does not exclude the diagnosis and molecular studies should be made in the case, we have shown positive immunochemistry staining in our tissue (Figure 2).

The frequency of ACTH-secreting pheochromocytomas is rare; in Ballav et al[16] cohort, they have found that pheochromocytomas consist of 5.2% of ectopic ACTH-secreting adenomas, whereas Falhammar et al[8] found a frequency of 1.2% among all Cushing cases.[4] Very recently, Elliott et al[17] published a meta-analysis of the patients with ectopic ACTH-and/or CRH-producing pheochromocytomas to date. To date, they identified 99 patients with ACTH- and/or CRH-producing pheochromocytoma (with 4 CRH-secreting and the rest of ACTH-secreting cases).

In our patient, a diagnosis of both hypercortisolemia and catecholamine excess was made because of an adrenal mass that was found incidentally. Her adrenal mass was compatible with a non-adenoma adrenal tumor, having cystic changes and high HU. She did not have any evidence of Cushing's syndrome, hypertensive attacks, or crisis suggesting pheochromocytoma, but she had resistant hypertension, which 4 different antihypertensive pills could control. She had diabetes mellitus, and she was overweight, which can indicate a subclinical Cushing's syndrome diagnosis. This makes the rule to screen patients with an adrenal incidentaloma for the possibility of subclinical hormones mandatory. This is the first case of ectopic Cushing's syndrome due to pheochromocytoma detected incidentally. The cases with this phenomenon emerged with either Cushingoid features and symptoms of pheochromocytomas like palpitations, headache, anxiety, or adrenal crisis.[6,7,11,12,13-17] This case represents a very rare cause of ectopic Cushing's syndrome due to a pheochromocytoma detected incidentally. After resection of the adrenal mass, endogenous hypercortisolemia and catecholamine metabolites excesses were resolved.

Conclusion

The clinical spectrum of ACTH-secreting pheochromocytomas may vary from asymptomatic cases to fatal cases. They are rare, but it is essential to consider them in the workup of a patient with adrenal incidentaloma. The treatment of these lesions can be lifesaving.

Informed Consent: Informed consent was obtained from the patient. As no directly patient-identifying information is presented, no specific further consent was obtained.

Peer-review: Externally peer-reviewed.

Author Contributions: Concept – İ.A., Design – İ.A., Supervision – İ.A., E.A., Materials-Data collection – A.L., Literature search – İ.A., Writing manuscript – İ.A., Critical review – İ.A., A.L., E.A.

Declaration of Interests: The authors have no conflict of interest to declare.

Funding: This study received no funding.

References

1. Beard CM, Sheps SG, Kurland LT, Carney JA, Lie JT. Occurrence of pheochromocytoma in Rochester, Minnesota, 1950 through 1979. *Mayo Clin Proc*. 1983;58(12):802-804.
2. Berends AMA, Buitenwerf E, de Krijger RR, et al. Incidence of pheochromocytoma and sympathetic paraganglioma in the Netherlands: a nationwide study and systematic review. *Eur J Intern Med*. 2018;51:68-73. [CrossRef]; Falhammar H, Calissendorff J, Höybye C. Frequency of Cushing's syndrome due to ACTH-secreting adrenal medullary lesions: a retrospective study over 10 years from a single center. *Endocrine*. 2017;55(1):296-302. (https://doi.org/10.1007/s12020-016-1127-y)
3. Bayraktar F, Kebapcilar L, Kocdor MA, et al. Cushing's syndrome due to ectopic CRH secretion by adrenal pheochromocytoma accompanied by renal infarction. *Exp Clin Endocrinol Diabetes*. 2006;114(8):444-447. [CrossRef]
4. O'Brien T, Young WF Jr, Davila DG, et al. Cushing's syndrome is associated with ectopic production of corticotrophin-releasing hormone, corticotrophin, and vasopressin by a phaeochromocytoma. *Clin Endocrinol (Oxf)*. 1992;37(5):460-467. [CrossRef]
5. Cheng X, Zhang M, Xiao Y, Li H, Zhang Y, Ji Z. Interleukin-6-producing pheochromocytoma as a new reason for fever of unknown origin: a retrospective study. *Endocr Pract*. 2018;24(6):507-511. [CrossRef]
6. Suzuki K, Miyashita A, Inoue Y, et al. Interleukin-6-producing pheochromocytoma. *Acta Haematol*. 1991;85(4):217-219. [CrossRef]
7. Heath H 3rd, Edis AJ. Pheochromocytoma associated with hypercalcemia and ectopic secretion of calcitonin. *Ann Intern Med*. 1979;91(2):208-210. [CrossRef]
8. Falhammar H, Kjellman M, Calissendorff J. Initial clinical presentation and spectrum of pheochromocytoma: a study of 94 cases from a single center. *Endocr Connect*. 2018;7(1):186-192. [CrossRef]
9. Kopetschke R, Slisko M, Kilisli A, et al. Frequent incidental discovery of phaeochromocytoma: data from a German cohort of 201 phaeochromocytoma. *Eur J Endocrinol*. 2009;161(2):355-361. [CrossRef]
10. Kirkby-Bott J, Brunaud L, Mathonet M, et al. Ectopic hormone-secreting pheochromocytoma: a francophone observational study. *World J Surg*. 2012;36(6):1382-1388. [CrossRef]
11. Gabi JN, Milhem MM, Tovar YE, Karem ES, Gabi AY, Khthir RA. Severe Cushing syndrome due to an ACTH-producing pheochromocytoma: a case presentation and review of the literature. *J Endocr Soc*. 2018;2(7):621-630. [CrossRef]
12. Roux G, Marchal G, Loubatières R. Phéochromocytome surrénalien latent révélé par un syndrome d'hypercorticisme. *Mem Acad Chir (Paris)*. 1955;81(27-28):847-852.
13. Forman BH, Marban E, Kayne RD, et al. Ectopic ACTH syndrome due to pheochromocytoma: case report and review of the literature. *Yale J Biol Med*. 1979;52(2):181-189.
14. Chen H, Doppman JL, Chrousos GP, Norton JA, Nieman LK, Udelsman R. Adrenocorticotropic hormone-secreting pheochromocytomas: the exception to the rule. *Surgery*. 1995;118(6):988-94; discussion 994. [CrossRef]
15. Cheng Y, Li J, Dou J, et al. Case report: three rare cases of ectopic ACTH syndrome caused by adrenal medullary hyperplasia. *Front Endocrinol*. 2021;12:687809. [CrossRef]
16. Ballav C, Naziat A, Mihai R, Karavitaki N, Ansorge O, Grossman AB. Mini-review: pheochromocytomas causing the ectopic ACTH syndrome. *Endocrine*. 2012;42(1):69-73. [CrossRef]
17. Elliott PF, Berhane T, Ragnarsson O, Falhammar H. Ectopic ACTH- and/or CRH-producing pheochromocytomas. *J Clin Endocrinol Metab*. 2021;106(2):598-608. [CrossRef]