A Young Male Patient With Multiple Thromboembolisms Associated With Factor V Leiden Mutation

Göksel Çınıer,[1] MD, Ahmet Öz,[1] MD, Ahmet Ilker Tekkesin,[1] MD, Mert İlker Hayıroğlu,[1] MD, Muhammed Keskin,[1] MD, *and* Şahin Avsar,[1] MD

Summary

Factor V Leiden (FVL) mutation is the most common hereditary thrombophilia. Association of this mutation with venous thrombosis is well established. However, there are several conflicting results regarding the association of FVL with arterial thrombosis, acute coronary syndrome, and intracardiac thrombosis. In this case report, we present a 44-year-old male patient with a medical history of both arterial and venous thrombosis who came to our emergency department with chest pain. After the initial evaluation he was diagnosed as having acute coronary syndrome and transthoracic echocardiography revealed an intracardiac apical thrombus. Coronary angiography showed non-critical stenosis. Thrombophilia panel was studied and the patient was found to be heterozygotic for FVL mutation. An apical thrombus was extracted surgically because of the high risk of systemic embolization. (Int Heart J 2016; 57: 654-656)

Key words: Acute coronary syndrome, Intracardiac thrombus, Normal coronary arteries, Apical thrombus

FVL mutation is the most common hereditary thrombophilia with a prevalence of heterozygous carriers of 3-5%.[1)] Association of this mutation with venous thromboembolism is well established. However, there are conflicting data on the association between FVL with arterial thrombosis and acute coronary syndrome. Intracardiac thrombosis (ICT) is a rare clinical condition, except those associated with cardiomyopathies, atrial fibrillation, and post-infarction period.[2)] Rare causes of ICT are hereditary thrombophilias and other hypercoagulable states.

Case Report

A 44 year-old male patient presented to the emergency department with worsening chest pain of 3 hours duration. His medical history revealed deep venous thrombosis in the left popliteal vein 4 years previously. He was on warfarin therapy then and 6 months later the therapy was stopped by his physician. Three months later he visited our emergency department complaining of sudden onset leg pain. Arterial Doppler ultrasonography revealed acute thrombus in the left popliteal artery and the patient underwent below knee peripheral by-pass surgery. After the surgery the patient was prescribed warfarin which he did not use. Physical examination revealed nothing important. His arterial blood pressure was 130/80 mmHg, Oxygen saturation was 98% at room air. His ECG showed 2 mm ST segment depression in leads V1 to V4. Routine blood tests were normal except elevated high sensitive cardiac troponin (342 ng/L, normal range: 0-34 ng/L) and CK-MB (48 μg/L, normal range: < 8.7 μg/L) levels. On transthoracic echocardiography, the left ventricular diastolic and systolic diameters were 5.7 and 4.3 cm, respectively, the ejection fraction calculated with the Simpson method was 43%, and the anterior and anteroseptum segments were hypokinetic. Apical 4-chamber view revealed an apical mobile thrombus (4.1 × 2.1 cm) (Figure 1). Right ventricular function and size were normal. Contrasted computed thorax tomography confirmed a thrombus in the left ventricle (Figure 2). Afterwards, he was admitted to the coronary intensive care unit with the initial diagnosis of acute coronary syndrome concomitant with intracardiac thrombus. Therapy consisting of aspirin, clopidogrel, low molecular weight heparin, a beta blocker, ace inhibitor, and statin was started. Since the patient was relatively young, had no known cardiological risk factors or history of multiple thrombotic events, a complete thrombophilia panel was obtained, including fibrinogen, protein C and S, antithrombin III, plasminogen activity, and lupus anticoagulant, all of which were within normal ranges [plasma fibrinogen level: 223 mg/dL (150-400 mg/dL), plasma protein C level: 93% (70-140%), plasma protein S level 87% (70-140%) plasma plasminogen level: 91% (75-130%), plasma antithrombin III level: 98% (80-130%)]. The anticardiolipin and β-2 glycoprotein antibodies were negative but he was found to be heterozygous for factor V Leiden. In order to avoid the risk of systemic embolism of the thrombus because of its large size and mobility, consultation with cardiovascular surgeons was undertaken. Meanwhile, coronary angiography was performed within 24 hours of admission and revealed non-critical stenosis (Figure 3). After the consultation with cardiovascular surgeons, thrombectomy surgery was

From [1] Department of Cardiology, Dr. Siyami Ersek Thoracic and Cardiovascular Surgery Center Training and Research Hospital, Istanbul, Turkey.

Address for correspondence: Ahmet Öz, MD, Department of Cardiology, Dr. Siyami Ersek Thoracic and Cardiovascular Surgery Center Training and Research Hospital, Istanbul 34656, Turkey. E-mail: drozahmet@gmail.com

Received for publication January 2, 2016. Revised and accepted February 24, 2016.

Released in advance online on J-STAGE September 1, 2016.

All rights reserved by the International Heart Journal Association.

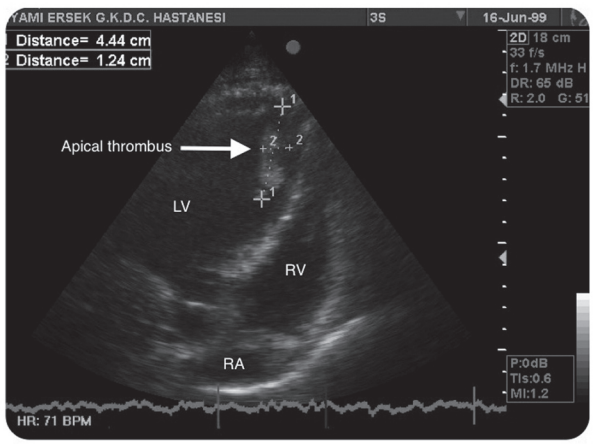

Figure 1. 2D transthoracic images showing the apical thrombus.

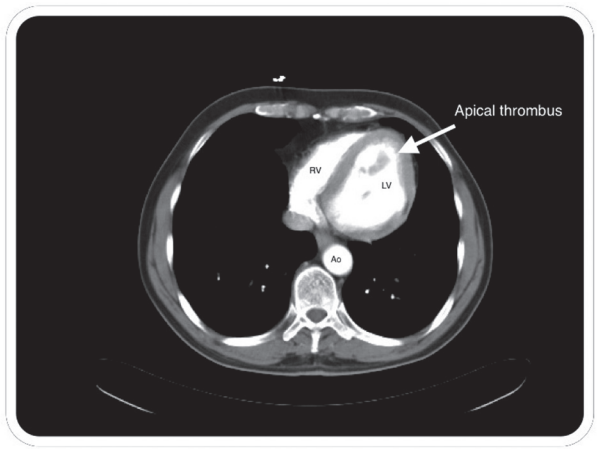

Figure 2. Thorax CT showing the apical thrombus.

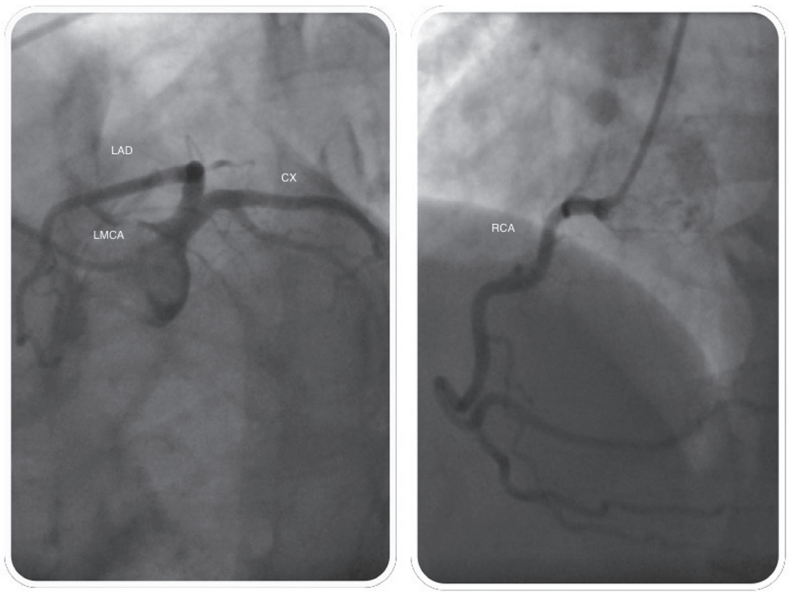

Figure 3. AG displaying normal coronary arteries.

planned. Sternotomy was performed and the thrombus was extracted successfully. The patient tolerated the surgery well and was started on warfarin therapy after the bleeding risk became negligible. The target INR level was determined to be between 2.5 – 3.5 due to patient's hereditary procoagulant condition. He was discharged from the hospital on the ninth day. Two months later a control transthoracic echocardiography was performed. The ejection fraction was consistent with the previous examination (40-45%) but there was no thrombus. Afterwards, he was followed up in an outpatient clinic.

Discussion

FVL is the most common known hereditary thrombophilia with the prevalence of heterozygous carriers being 3% to 5%.[1] FVL is also the most common known hereditary thrombophilia associated with venous thromboembolism. Heterozygous carriers of FVL have 3-8-fold increased risk, while homozygous carriers have 90-fold increased risk.[3] Although the association between venous thromboembolism and FVL is well established, it is still controversial as to whether FVL is a risk factor for arterial thrombosis, acute coronary syndrome, and intracardiac thrombosis.

There are conflicting data on FVL as a risk factor for myocardial infarction (MI). The Copenhagen City Heart Study covered almost 31,000 individuals from 35 studies and suggested that FVL is not associated with MI or ischemic stroke.[4] Dacosta, *et al* investigated 75 patients under the age of 45 who were admitted to the hospital for acute myocardial infarction. Twenty-two had normal coronary arteriography (group 1) and 53 had significant coronary artery disease (group 2). Hereditary thrombophilia was more often found in group 1 than group 2, but the difference was not statistically significant.[5]

On the other hand, Rosendal, *et al* conducted a case control study among 84 young women aged 18 to 44 years old

with their first MI and compared them with 388 women in the control group. They concluded that FVL increases the risk of MI in young women and the risk is increased when adjusted for major cardiovascular risk factors.[1] Van der Water, *et al* examined the frequency of FVL and prothrombin variant G20210A in patients aged less than 50 with no significant coronary stenosis 3 to 4 weeks after MI. They found that the frequency of FVL and prothrombin variant G20210A had increased in the study group.[6]

Girolami, *et al* studied 25 patients with hereditary thrombophilia who presented with intracardiac thrombosis. Six of them were found to be heterozygous carriers of the FVL mutation. The characteristics of intracardiac thrombus in hereditary thrombophilia patients did not seem to be different from the intracardiac thrombus seen in the postinfarct period or during atrial fibrillation.[2]

The result of several studies in the literature suggest that FVL mutation can be a significant risk factor for myocardial infarction, especially for young patients who have normal or near-normal (< 50% stenosis) coronary arteries. The risk is increased in the presence of other major cardiovascular risk factors, especially smoking.

The present case is the first one known in the literature that a patient heterozygous for FVL mutation, presented with multiple thromboses in both venous and arterial systems, including in the left ventricle. Although apical thrombus is a well-known complication of acute coronary syndrome, it is usually present in cases of acute anterior wall myocardial infarction with apical akinesia.[7] In our case, the cardiac apex was mildly hypokinetic. In the absence of other risk factors, the patient's hereditary predisposition to thrombosis is the main cause of the intracardiac thrombus. The patient should have been evaluated for intracardiac thrombosis after the diagnosis of acute popliteal artery occlusion 3 months previously. Arterial embolism from the apical thrombus is the only explanation in our case for multiple arterial thromboses including within the left popliteal artery and coronary vasculature causing acute coronary syndrome.

Surgical thrombectomy was chosen as the therapeutic option because the thrombus was relatively large in size and mobile, which carries a high risk of systemic embolization.

In conclusion, hereditary thrombophilias should be screened for in young patients who present with acute coronary syndrome and who have non-critical stenosis in coronary angiography. Also, there is an increased risk for intracardiac thrombosis in thrombophilic patients and careful cardiac evaluation in all patients with hereditary thrombophilia is warranted.

Disclosure

Conflicts of interest statement: The authors certify that they have no affiliations with or involvement in any organization or entity with any financial interest (such as honoraria; educational grants; participation in speakers' bureaus; membership, employment, consultancies, stock ownership, or other equity interest; and expert testimony or patent-licensing arrangements), or non-financial interest (such as personal or professional relationships, affiliations, knowledge or beliefs) in the subject matter or materials discussed in this manuscript.

References

1. Rosendaal FR, Siscovick DS, Schwartz SM, *et al*. Factor V Leiden (resistance to activated protein C) increases the risk of myocardial infarction in young women. Blood 1997; 89: 2817-21.
2. Girolami A, de Marinis GB, Treleani M, Tasinato V, Girolami B. Congenital thrombophilia and intracardiac thrombosis: probably an underdiagnosed event. Cardiol Res 2013; 4: 109-15.
3. Boroumand M, Ziaee S, Anvari M, Anvari MS, Jalali A, Goodarzynejad H. The association between Factor V Leiden with the presence and severity of coronary artery disease. Clin Biochem 2014; 47: 356-60.
4. Juul K, Tybjærg-Hansen A, Steffensen R, Kofoed S, Jensen G, Nordestgaard BG. Factor V Leiden: the Copenhagen city heart study and 2 meta-analyses. Blood 2002; 100: 3-10.
5. Dacosta A, Tardy-Poncet B, Isaaz K, *et al*. Prevalence of factor V Leiden (APCR) and other inherited thrombophilias in young patients with myocardial infarction and normal coronary arteries. Heart 1998; 80: 338-40.
6. Van de Water NS, French JK, Lund M, Hyde TA, White HD, Browett PJ. Prevalence of factor V Leiden and prothrombin variant G20210A in patients age < 50 years with no significant stenoses at angiography three to four weeks after myocardial infarction. J Am Coll Cardiol 2000; 36: 717-22.
7. Lee JM, Park JJ, Jung HW, *et al*. Left ventricular thrombus and subsequent thromboembolism, comparison of anticoagulation, surgical removal, and antiplatelet agents. J Atheroscler Thromb 2013; 20: 73-93.