CASE REPORT

Internal limiting membrane detachment associated with papilloedema following brain metastasis in a child with Ewing sarcoma

Ayse Ebru Bahadir[1,*], **Dilek Guven**[2], **Ozgul Altintas**[2]

[1] Acibadem Mehmet Ali Aydinlar University School of Medicine, Istanbul, Turkey. [2] Acibadem Maslak Hospital, Istanbul, Turkey.

*Correspondence: Ayse Ebru Bahadir, Acibadem Mehmet Ali Aydinlar University School of Medicine Kayışdağı Cad. No:32, 34752 Ataşehir/ Istanbul, Turkey. Email: ebrubahadir@gmail.com

How to cite this article: Bahadir AE, Guven D, Altintas O. Internal limiting membrane detachment associated with papilloedema following brain metastasis in a child with Ewing sarcoma. Arch Clin Cases. 2025;12(4):148-153. doi: 10.22551/2025.49.1204.10329

ABSTRACT

This case report presents initial and follow-up findings of a rare case of bilateral internal limiting membrane (ILM) detachment and sub-ILM hemorrhage in a 7-year-old child with Ewing sarcoma, associated with papilloedema due to a brain metastasis and the use of optical coherence tomography (OCT) in the evaluation and follow-up. The child was diagnosed with Ewing sarcoma and she was referred to the ophthalmology clinic because of blurry vision, anisocoria, and strabismus one week after the operation for brain metastasis. Fundus examination showed bilateral grade IV papilloedema, well-defined dome-shaped area extending towards the optic discs with inferiorly located hemorrhage. OCT revealed bilateral ILM detachment surrounded with a ring-shaped retinal elevation and inferiorly located sub-ILM hemorrhage. On the follow-up examinations OCT showed decrease of height of ILM detachment with resolution of sub-ILM hemorrhage. ILM detachment associated with papilloedema due to a brain metastasis is an exceedingly rare occurrence, making this case particularly significant in understanding ocular manifestations of intracranial pathology. OCT plays a crucial role in diagnosing and monitoring the progression of ILM detachment and associated sub-ILM hemorrhage, offering invaluable insights into the pathophysiology of raised intracranial pressure. Recognizing ocular signs such as papilloedema is critical for early detection of intracranial complications in pediatric patients.

KEYWORDS: Ewing's sarcoma; papilloedema; internal limiting membrane detachment; sub-ILM hemorrhage; optical coherence tomography

INTRODUCTION

Internal limiting membrane (ILM) detachment and sub-ILM hemorrhage have been reported in association with various conditions, including Valsalva retinopathy, Purtscher's retinopathy, hypertensive retinopathy, Terson's syndrome, ruptured macroaneurysm, and acute central retinal artery occlusion [1-4]. In the pediatric population, ILM detachment has primarily been linked to abusive head trauma, with no other cases reported in the literature [5,6]. However, to the best of our knowledge, ILM detachment associated with intracranial tumors, particularly brain metastasis, has not been previously documented. This case report presents the initial and follow-up findings of an unusual case of bilateral ILM detachment and sub-ILM hemorrhage associated with papilloedema in a 7-year-old child who underwent surgery for brain metastasis of Ewing sarcoma, emphasizing the novelty and diagnostic challenges of this presentation.

Received: September 2025; **Accepted after review:** November 2025; **Published:** November 2025.

CASE PRESENTATION

A 7-year-old child was admitted to the hospital with swelling and pain in the medial aspect of the left thigh. An overview of the patient's clinical course is shown in Figure 1. She was diagnosed with Ewing sarcoma and received chemotherapy, radiotherapy, and underwent tumor excision surgery. Following treatment, she was discharged and returned to her home country. Three months later, she was re-hospitalized with complaints of headache and vomiting. Cranial MRI and MR angiography revealed a hemorrhagic lesion, and she was monitored in the intensive care unit for two days. After discharge, she developed left-sided facial paralysis, anisocoria, and strabismus, and was subsequently admitted again. She received follow-up and treatment in her country for one month, and was then referred to our hospital. Laboratory tests showed an activated partial thromboplastin time of 28.6s (reference: 21-36), a prothrombin time of 13.0s (reference: 9.3-14.0), and international normalized ratio of 1.10 (reference:0.8-1.25). Emergency cranial MRI revealed a right posterior parietal metastatic lesion measuring 70 x 55 x 62mm with intralesional hemorrhage, causing compression

of the mesencephalon, leftward midline shift, and uncal herniation. There was no direct involvement of the visual pathways. The patient underwent mass resection, followed by chemotherapy, corticosteroid therapy, and radiotherapy.

One week after surgery, the patient was referred to the ophthalmology clinic with complaints of blurred vision, anisocoria, and strabismus. Her visual acuity was 5/10 in the right eye, while the left eye showed only light perception and



Fig. 1. Timeline of patient's clinical progression.

a relative afferent pupillary defect (RAPD). Bilateral restriction of horizontal eye movements and right hypotropia were observed. Fundus examination revealed bilateral grade IV papilloedema with engorged retinal vessels, a well-defined dome-shaped elevation extending toward the optic discs with inferiorly located hemorrhage, macular striae, and hard exudates (Figure 2). Optical coherence tomography (OCT) demonstrated bilateral ILM detachment surrounded by a ring-shaped retinal elevation, intraretinal hyperreflective dots consistent with hard exudates, and inferiorly located sub-ILM hemorrhage. In the left eye, there was subretinal fluid localized under the retinal elevations. The findings were more pronounced in the left side, with a greater area and height. ILM detachment extended to the elevated optic discs (Figure 3).

At the third postoperative week, visual acuity was 6/10 in the right eye and no light perception in the left eye. There was esotropia and hypertropia of the left eye and bilateral restriction of abduction. Fundus examination showed papilloedema with palor of the optic discs and bilateral ILM detachment. OCT demonstrated a decrease in the height of ILM detachment and partial resolution of sub-ILM hemorrhage, sub-ILM cavity, and subretinal fluid, along with bilateral hyperreflective intraretinal deposits (Figure 3).

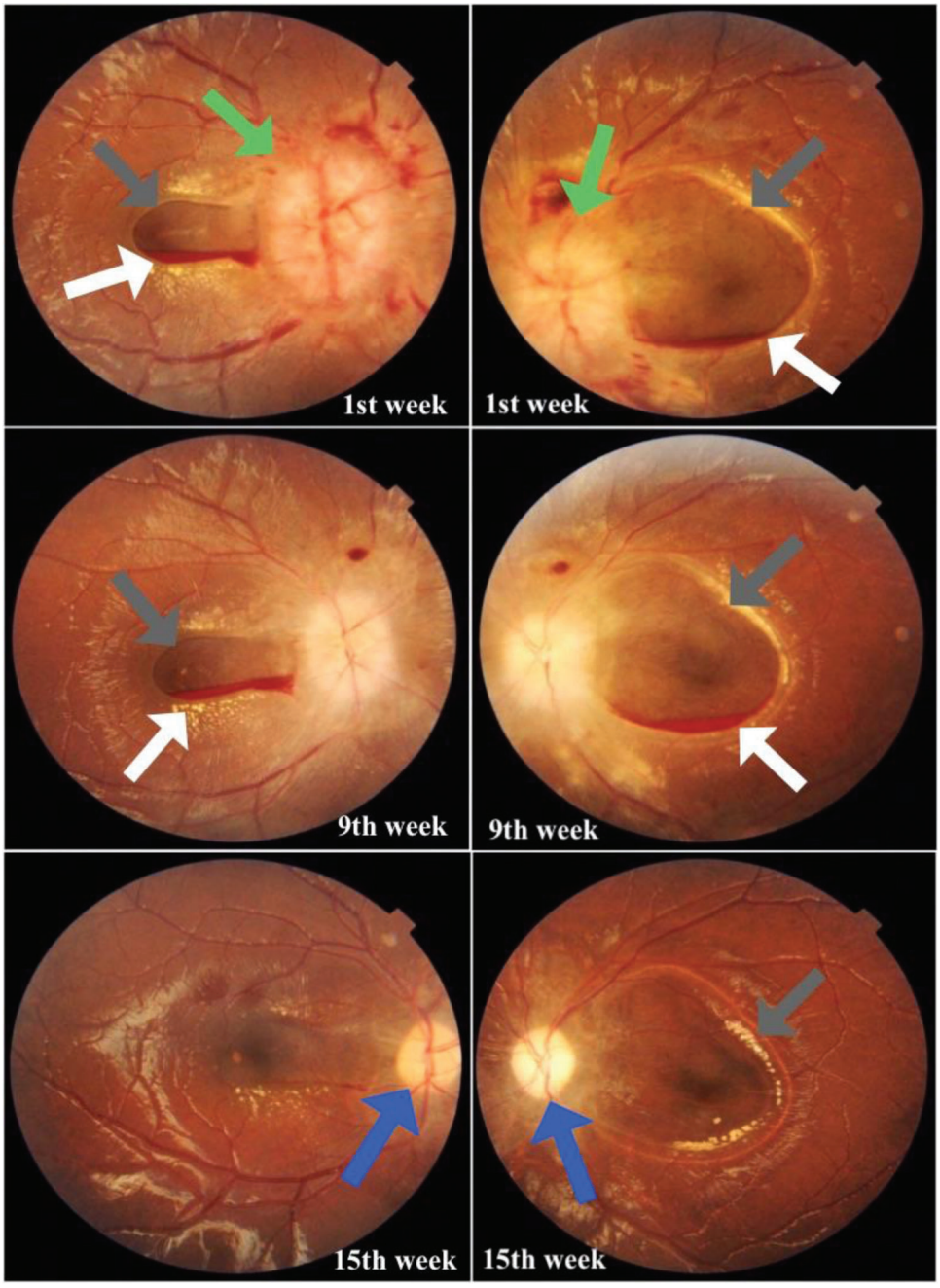

Fig. 2. Fundus photographs of the right (left column) and left (right column) eyes at postoperative 1st, 9th, and 15th weeks. Green arrow = papilloedema, white arrow = inferiorly located hemorrhage, gray arrow = well-defined dome-shaped area, blue arrow = pallor of the optic disc.

At the 15th postoperative week, visual acuity was 7/10 in the right eye and 1/10 in the left eye. There was exotropia and anisocoria, and RAPD was present in the left eye. On fundus examination, resolution of sub-ILM hemorrhage was seen, but there was bilateral optic atrophy, more pronounced on the left eye (Figure 2). OCT demonstrated a further decrease in the height of ILM detachment (Figure 3).

At the 9th postoperative month, the patient's last ophthalmologic follow-up revealed visual acuity of 7/10 in the right eye and 0.5/10 in the left eye. In the primary position, the eyes were orthophoric, and RAPD was present in the left eye. Fundus examination demonstrated bilateral optic atrophy, more pronounced in the left eye. OCT confirmed complete resolution of the ILM detachment (Figure 4).

The patient's most recent oncologic evaluation, performed on August 14, 2024, showed a good general condition with normal clinical findings. Laboratory tests and imaging results were stable, and she was advised to continue routine follow-up visits. No neurological sequelae were observed, indicating a stable long-term outcome.

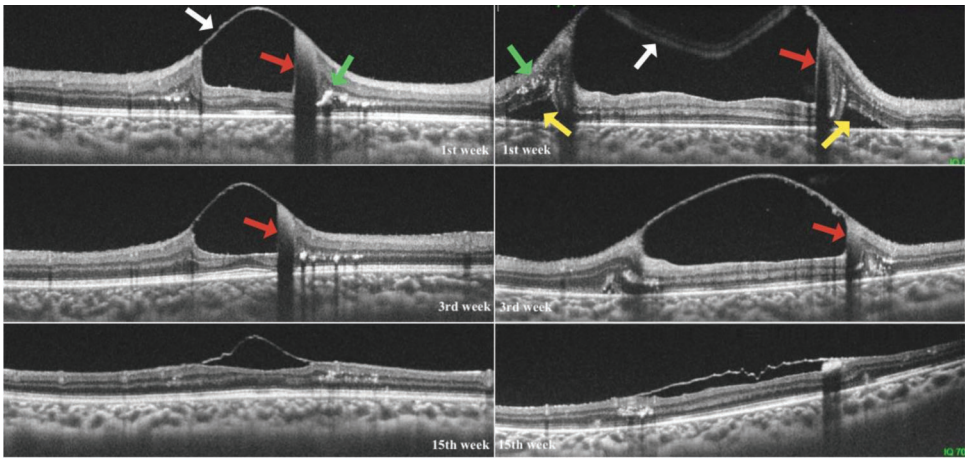

Fig. 3. Optical coherence tomography scans of the right (left column) and left (right column) eyes at postoperative 1st, 3rd, and 15th weeks. White arrow = ILM detachment, red arrow = Sub-ILM hemorrhage, yellow arrow = subretinal fluid, green arrow = intraretinal hyperreflective dots.

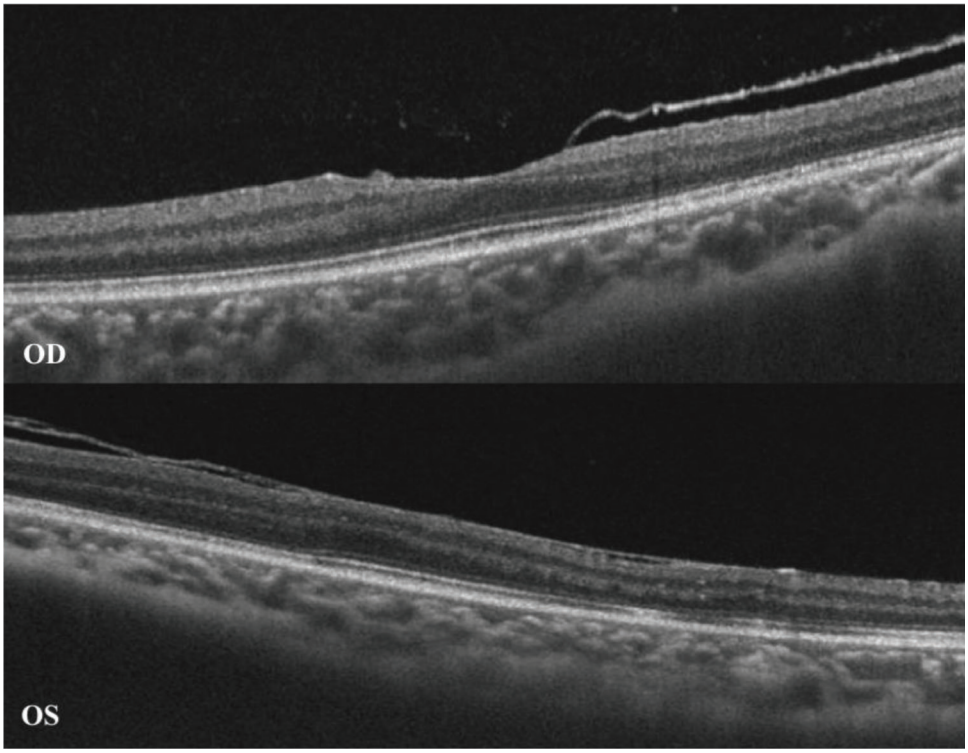

Fig. 4. Optical coherence tomography scans of the right (OD) and left (OS) eyes at postoperative 9th month.

DISCUSSION

Spontaneous resolution of ILM detachment and hemorrhage may occur within weeks to months following a period of observation; however, this is usually seen in smaller hemorrhages or in young patients without any preexisting retinal disease [1,2,7,8]. In contrast, larger hemorrhages may result in prolonged contact between hemoglobin and retinal tissue, potentially leading to retinal toxicity and irreversible damage [2,9]. Considering the patient's age, the location, and the height of the sub-ILM hemorrhage, various management options –including observation, Nd:YAG laser membranectomy, intravitreal tPA and gas injection, or pars plana vitrectomy– can be considered depending on the visual potential and general health condition of the patient [1-4,7,8]. In this case, a conservative approach was preferred because the patient was young, had no known retinal pathology, the intraretinal hemorrhages were small and bilateral, and her systemic condition was poor. The sub-ILM hemorrhage resolved spontaneously within 15 weeks after tumor resection.

Papilloedema can compromise axoplasmic flow and compress small vessels within the optic nerve head, predisposing the optic disc to ischemic injury [10]. This mechanism may explain the bilateral optic atrophy, more pronounced in the left eye. Another plausible factor is retrograde retinal ganglion cell atrophy secondary to mass effect of the metastatic lesion on the midbrain and optic pathways, which could further exacerbate optic nerve damage [11]. In a study unilateral involvement of optic atrophy was described in 3.5% of patients [10]. Asymmetric papilloedema, as seen here, may stem from asymmetries in the bony optic canal that interfere with the flow of cerebrospinal fluid between the perioptic subarachnoid spaces [10]. Also, faster restoration of blood circulation in the right eye may have helped preserve vision in the right eye.

OCT is a valuable imaging tool that can complement clinical findings in the diagnosis and monitoring of idiopathic intracranial hypertension [12]. It enables visualization of optic nerve head swelling characteristic of papilloedema, as well as changes in the retinal nerve fiber layer and retinal pigment epithelium/Bruch's membrane that reflect both acute and chronic alterations in intracranial pressure [13,14].

While relatively large sub-ILM cavities may be apparent on fundus examination, smaller cavities are best visualized using OCT, which provides detailed cross-sectional assessment of the retinal layers [3]. Clinically, differentiating between subhyaloid and sub-ILM hemorrhage can be challenging [8]. However, in this patient, OCT demonstrated a ring shaped retinal elevation with a hyper-reflective anterior boundary consistent with ILM, confirming the sub-ILM location of the blood. This highlights the role of OCT not only in diagnosis but also in longitudinal follow-up to confirm anatomic recovery, rather than serving as a mere descriptive imaging tool.

ILM hemorrhage in this case may have been caused by raised intracranial pressure and papilloedema, which increased retinal venous pressure and led to rupture of perifoveal superficial capillaries [5,6]. Other possible contributing factors include systemic coagulopathy, radiotherapy- or chemotherapy-induced vascular fragility, and altered cerebrospinal fluid dynamics in the optic nerve sheath region [7,15,16]. The hard exudates observed suggest a chronic process, likely reflecting prolonged vascular leakage and retinal traction due to ILM detachment and subretinal fluid [17].

From a clinical perspective, this case underscores the importance of recognizing ILM detachment as a potentially secondary manifestation of elevated intracranial pressure in patients with intracranial tumors or metastases. Early neuroimaging and interdisciplinary management are crucial to prevent irreversible visual loss. Furthermore, OCT proves invaluable not only in identifying subtle ILM elevations but also in differentiating their etiology and guiding management decisions.

CONCLUSION

OCT plays a crucial role in the evaluation and follow-up of ILM detachment and sub-ILM hemorrhage. To the best of our knowledge, this is the first report describing the use of OCT in assessing and monitoring ILM detachment and sub-ILM hemorrhage associated with a brain metastasis. This case illustrates the ILM detachment secondary to increased intracranial pressure is a rare but clinically significant manifestation. Furthermore, this case underscores the importance of timely ophthalmologic evaluation in pediatric patients with neurological tumors and visual complaints, as early ocular assessment may provide crucial information about underlying intracranial pathology and guide multidisciplinary management.

DECLARATIONS

Ethics Statement, consent for publication

Written informed consent was obtained from the patient's legal guardian for publication of this case report and any accompanying images. A copy of the written consent is available for review by the Editor-in-Chief of this journal. The study adhered to the tenets of the Declaration of Helsinki. Ethical approval was obtained from the Institutional Review Board of Acibadem University, Istanbul, Turkey (IRB protocol no: 2023-17/591).

Availability of data and materials

The data and materials of this case report are available from the corresponding author upon reasonable request.

Competing interests

None of the authors have any proprietary interests or conflicts of interest related to this submission.

Funding

There is not any financial support for this study.

Acknowledgements

The authors would like to acknowledge that this case was previously presented in abstract form at the 20th European VitreoRetinal Society (EVRS) 2023 Annual Meeting (Cappadoccia, Turkiye): "Bilateral internal limiting membrane detachment and papilledema as a complication of brain metastasis secondary to Wilm's tumor" (abstract [0223], by Dilek Güven and Özgül Altıntaş, Acıbadem Maslak Hospital, İstanbul, Türkiye).

REFERENCES

1. Asteris P, Kalogeropoulos D, Moussa G, et al. A brief review of Valsalva retinopathy. *Med. Hypothesis Discov Innov Optom*. 2022; 3(1):42-7. doi: 10.51329/mehdioptometry149.
2. Hussain RN, Stappler T, Hiscott P, et al. Histopathological changes and clinical outcomes following intervention for sub-internal limiting membrane haemorrhage. *Ophthalmologica*. 2020;243(3):217-23. PMID: 31743895x. doi: 10.1159/000502442.
3. Kumar V, Chanana B. Sub-internal limiting membrane cavity in anaemic retinopathy evident on spectral domain optical coherence tomography. *Clin Exp Optom*. 2014 Jan;97(1):80-3. PMID: 23656561. doi: 10.1111/cxo.12032.
4. Venkatesh R, Jayadev C, Sridharan A, et al. Internal limiting membrane detachment in acute central retinal artery occlusion: a novel prognostic sign seen on OCT. *Int J Retina Vitreous*. 2021 Sep 3;7(1):51. PMID: 34479634; PMCID: PMC8418027. doi: 10.1186/s40942-021-00323-7.
5. Kelly JP, Feldman KW, Weiss A. Optical coherence tomography and visual outcomes in pediatric abusive head trauma. *Retin Cases Brief Rep*. 2024 Mar 1;18(2):225-9. PMID: 36121805. doi: 10.1097/ICB.0000000000001353.
6. Ksiaa I, Ghachem M, Besbes H, et al. Swept-source OCT findings in shaken baby syndrome: case report. *BMC Ophthalmol*. 2020 Oct 7; 20(1):396. PMCID: PMC7541327. doi: 10.1186/s12886-020-01666-9.
7. De Maeyer K, Van Ginderdeuren R, Postelmans L, et al. Sub-inner limiting membrane haemorrhage: causes and treatment with vitrectomy. *Br J Ophthalmol*. 2007 Jul;91(7):869-72. PMID: 17229799; PMCID: PMC1955625. doi: 10.1136/bjo.2006.109132.
8. Brar AS, Ramachandran S, Takkar B, et al. Characterization of retinal hemorrhages delimited by the internal limiting membrane. *Indian J Ophthalmol*. 2024 Jan 1;72(Suppl 1):S3-S10. PMID: 38131534; PMCID: PMC10833172. doi: 10.4103/IJO.IJO_266_23.
9. Srinivasan S, Kyle G. Subinternal limiting membrane and subhyaloid haemorrhage in Terson syndrome: the macular 'double ring' sign. *Eye (Lond)*. 2006 Sep;20(9):1099-101. PMID: 16227979. doi: 10.1038/sj.eye.6702134.
10. Attia R, Fitoussi R, Mairot K, et al. Risk factors associated with progression from papilloedema to optic atrohy: results from a cohort of 113 patients. *BMJ Open Ophth*. 2023 Nov; 8(1):e001375. PMID: 37935563; PMCID: PMC10632874. doi: 10.1136/bmjophth-2023-001375.
11. Goto K, Miki A, Yamashita T, et al. Sectoral analysis of the retinal nerve fiber layer thinning and its association with visual field loss in homonymous hemianopia caused by post-geniculate lesions using spectral-domain optical coherence tomography. *Graefes Arch Clin Exp Ophthalmol*. 2016 Apr;254(4):745-56. PMID: 26446718; PMCID: PMC4799802. doi: 10.1007/s00417-015-3181-1.
12. Malhotra K, Padungkiatsagul T, Moss HE. Optical coherence tomography use in idiopathic intracranial hypertension. *Ann Eye Sci*. 2020 Mar;5:7. PMID: 32405617; PMCID: PMC7220123. doi: 10.21037/aes.2019.12.06.
13. Wang JK, Kardon RH, Ledolter J, et al. Peripapillary Retinal Pigment Epithelium Layer Shape Changes From Acetazolamide Treatment in the Idiopathic Intracranial Hypertension Treatment Trial. *Invest Ophthalmol Vis Sci*. 2017 May 1;58(5):2554-65. PMID: 28492874; PMCID: PMC5425231. doi: 10.1167/iovs.16-21089.
14. Anand A, Pass A, Urfy MZ, et al. Optical coherence tomography of the optic nerve head detects acute changes in intracranial pressure. *J Clin Neurosci*. 2016 Jul;29:73-6. PMID: 26898579. doi: 10.1016/j.jocn.2015.12.016.
15. Yang EH, Marmagkiolis K, Balanescu DV, et al. Radiation-Induced Vascular Disease-A State-of-the-Art Review. *Front Cardiovasc Med*. 2021 Mar 30;8:652761. PMID: 33860001; PMCID: PMC8042773. doi: 10.3389/fcvm.2021.652761.
16. Mizrachi A, Ben-Aharon I, Li H, et al. Chemotherapy-induced acute vascular injury involves intracellular generation of ROS via activation of the acid sphingomyelinase pathway. *Cell Signal*. 2021 Jun;82:109969. PMID: 33647448; PMCID: PMC10402763. doi: 10.1016/j.cellsig.2021.109969.
17. Ariello LE, Mello LGM, Pimentel SLG, et al. Chorioretinal abnormalities in idiopathic intracranial hypertension: case reports. *Int J Retina Vitreous*. 2022 Jul 22;8(1):48. PMID: 35869502; PMCID: PMC9308292. doi: 10.1186/s40942-022-00403-2.