Clear Corneal Wound Infection After Phacoemulsification

C. Banu Cosar, MD; Elisabeth J. Cohen, MD; Christopher J. Rapuano, MD; Peter R. Laibson, MD

Objective: To evaluate clear corneal wound infections after phacoemulsification.

Materials and Methods: The medical records of 7 patients with clear corneal wound infections after phacoemulsification were reviewed retrospectively. Data that were reviewed included patient age, sex, onset of symptoms and signs after surgery, possible risk factors for infection, concomitant ocular disease, use of perioperative prophylactic antibiotics and steroids, culture and antibiotic sensitivity results, treatment regimen, and outcome.

Results: The median onset of signs and symptoms after surgery was 10 days (range, 4-60 days). Corneal cultures yielded methicillin-resistant *Staphylococcus aureus* in 2 cases, *Streptococcus pneumoniae* in 1 case, and *Staphylococcus epidermidis* in 1 case. Cultures yielded no microorganisms for 1 patient. Corneal cultures were not obtained in 2 patients. In 3 of the 4 culture-positive cases, the isolated microorganisms were resistant to the perioperative prophylactic antibiotics (fluoroquinolones and tobramycin) that were used. No possible risk factors were noted except use of topical steroids 4 times a day without antibiotic coverage for iritis before referral in one of our patients. Six of these 7 wound infections healed with topical antibiotic therapy. One of the patients required lamellar keratectomy and conjunctival flap for complete healing. In 4 of the 7 cases, best-corrected visual acuity at the last follow-up visit was better than 20/40.

Conclusions: Clear corneal wound infection after phacoemulsification is a serious complication of cataract surgery. Infections are caused by gram-positive organisms sensitive to bacitracin and the combination of trimethoprim-sulfamethoxazole but often resistant to aminoglycosides and/or fluoroquinolones.

Arch Ophthalmol. 2001;119:1755-1759

From the Cornea Service, Wills Eye Hospital and the Department of Ophthalmology, Jefferson Medical College, Thomas Jefferson University, Philadelphia, Pa.

WOUND infection after cataract extraction is a rare complication. There is little published data on corneoscleral wound infections after extracapsular cataract extraction and no data are available on clear corneal wound infections after phacoemulsification.[1-6] In this article, we report 7 cases of clear corneal wound infections after phacoemulsification.

RESULTS

There were 5 female and 2 male patients in the study. The median age of the patients at the time of surgery was 78 years (age range, 55-86 years) (**Table 1**). The median onset of signs and symptoms after surgery was 10 days (range, 4-60 days).

Wound infections at the sutureless clear corneal cataract incisions were located superiorly in 3 patients (cases 1, 5, and 6) and temporally in 4 patients. There was associated hypopyon in 5 (cases 1 and 3 through 6) of the 7 patients. An epithelial defect overlying the infectious infiltrate was present in all of the corneas except patients 3 and 6 (**Figure**). At presentation, in addition to the wound infection, 2 patients had endophthalmitis (cases 1 and 5), and 1 patient had endophthalmitis and scleritis (case 6). In 2 patients (cases 3 and 4), the hypopyon was thought to be a sterile reaction to the corneal infection. For patient 1, pars plana vitrectomy and a vitreous biopsy were performed and intravitreal injections of amikacin sulfate, vancomycin hydrochloride, and dexamethasone sodium phosphate were administered. For patients 5 and 6, anterior chamber and vitreous taps were performed and intravitreal injections of amikacin, vancomycin, and dexamethasone were administered. Vitreous cultures yielded no microorganisms in all 3 of these cases. Anterior chamber cultures yielded no microorganisms in case 5 and yielded methicillin-resistant *Staphylococcus aureus* in case 6.

©2001 American Medical Association. All rights reserved.
Downloaded From: https://jamanetwork.com/ on 03/15/2022

MATERIALS AND METHODS

In this retrospective case series, we analyzed the medical records of 7 patients who were referred to the Cornea Service at Wills Eye Hospital, Philadelphia, Pa, with clear corneal wound infection after sutureless phacoemulsification. The patients were seen from January 1, 1994, to August 1, 2000. Information that was reviewed included patient age, sex, onset of signs and symptoms after surgery, possible risk factors for infection, concomitant ocular disease, use of perioperative prophylactic antibiotics and steroids, culture and antibiotic sensitivity results, treatment regimen, and outcome. In addition, the involved cataract surgeons were sent a questionnaire regarding their cataract surgery practices and any possible break in the aseptic technique.

Corneal cultures were obtained in all patients except cases 1 and 5 because they were treated with fortified antibiotics for endophthalmitis prior to referral. Corneal cultures yielded methicillin-resistant *S aureus* in 2 eyes, *Streptococcus pneumoniae* in 1 eye, and *Staphylococcus epidermidis* in 1 eye. Cultures yielded no microorganisms in 1 eye.

All 7 cataract surgeons replied to the questionnaire regarding their phacoemulsification practices. They all denied a possible break in the aseptic technique with their patient and reported that the surgery was uncomplicated. Preoperative 0.3% ciprofloxacin hydrochloride was used prophylactically in 5 of the 7 eyes. None of them reported use of antibiotics in the irrigation fluid. Five surgeons used topical povidine-iodine solution on the conjunctival surface just before incision, 1 surgeon used postoperative subconjunctival injections of gentamicin sulfate and betamethasone sodium phosphate, and 1 surgeon used a collagen shield soaked in a combination of 0.3% ciprofloxacin and 1% prednisolone acetate for prophylaxis. Overnight postoperative patching was reported in 4 of the 7 patients.

Postoperative prophylactic antibiotic drops were used in all patients. The antibiotics that were used were 0.3% ciprofloxacin in 3, 0.3% tobramycin sulfate in 2, a combination of 0.3% ciprofloxacin and 0.3% tobramycin in 1, and 0.3% ofloxacin in 1 patient. In 3 of the 4 culture-positive cases, the isolated bacteria were resistant to the prophylactic antibiotics used (fluoroquinolones and tobramycin) (**Table 2**). Postoperative steroids (1% prednisolone, 0.1% dexamethasone) were used in all 7 patients. In 3 of the 7 patients, postoperative topical nonsteroidal anti-inflammatory drugs (0.1% diclofenac sodium and 0.5% ketorolac tromethamine) were also used.

No history of concomitant ocular disease except cornea guttata in 2 patients was noted. There was no long-term use of topical eye medications. None of the patients had diagnoses of diabetes mellitus, immunocompromise, preoperative external ocular infections, eyelid

Table 1. Summary of the Data of Patients With Clear Corneal Wound Infection*

Patient No./Sex/ Age, y	Onset of Signs and Symptoms, d	Associated Scleral Extension or Endophthalmitis	Type of Organism		Type of Prophylactic Topical Antibiotic Received		Susceptibility to Prophylactic Antibiotic
			Yielded From Corneal Culture	Yielded From Vitreous and/or Anterior Chamber Fluid Culture	Preoperatively	Postoperatively	
1/M/55	4	Endophthalmitis	Culture not obtained	No growth (vitreous)	. . .	Tobra q2h on POD 1, then qid	. . .
2/F/83	11	. . .	No growth	. . .	. . .	Tobra qid	. . .
3/F/69	60	. . .	*Staphylococcus epidermidis*	. . .	Cipro qid starting 2 days preoperatively	Cipro q2h on POD 1, then qid	Resistant to cipro
4/F/78	23	. . .	*Streptococcus pneumoniae*	. . .	Cipro tid starting 3 days preoperatively	Cipro q4h	Sensitive to cipro
5/F/65	10	Endophthalmitis	Culture not obtained	No growth (vitreous and anterior chamber)	Cipro qid starting 2 days preoperatively	Cipro q2h on POD 1, then qid	. . .
6/F/86	5	Both scleral extension and endophthalmitis	MRSA	No growth (vitreous); MRSA (anterior chamber)	Cipro starting on the day of surgery	Cipro qid; tobra qid	Resistant to cipro and tobra
7/M/82	10	. . .	MRSA	. . .	Cipro starting on the day of surgery	Oflo qid	Resistant to cipro and oflo

*BCVA indicates best-corrected visual acuity; ellipses, not applicable; tobra, tobramycin; qh, every hour; POD, postoperative day; qid, 4 times daily; vanco, vancomycin; IV, intravenous; genta, gentamicin; pred, prednisolone acetate; cefa, cefazolin; PCO, posterior capsular opacification; cipro, ciprofloxacin; oflo, ofloxacin; bid, 2 times daily; tid, 3 times daily; levoflo, levofloxacin; qd, every day; MRSA, methicillin-resistant *Staphylococcus aureus*; and IOL, intraocular lens.

©2001 American Medical Association. All rights reserved.
Downloaded From: https://jamanetwork.com/ on 03/15/2022

abnormalities, or dry eye syndrome that could potentially predispose to infection. Use of topical steroids 4 times a day for postoperative iritis without antibiotic coverage before referral to us in case 3 was a possible risk factor for the late-onset wound infection.

Our initial treatment for bacterial ulcers was fortified tobramycin sulfate, 15 mg/mL, alternating with cefazolin sodium, 50 mg/mL, every 30 minutes in 3 patients; fortified tobramycin sulfate, 15 mg/mL, alternating with vancomycin hydrochloride, 50 mg/ mL, every 30 minutes in 3 patients; and 0.3% ofloxacin every 30 minutes in 1 patient. Our initial treatment regimen also included topical steroids in 2 patients. The topical antibiotics were then tapered, and topical steroids were added to the regimen of 2 more patients depending on the healing response of the ulcer. Except for patient 3, the patients in all of the cases were admitted to the hospital. Patient 7 was admitted twice as his ulcer flared up after it was almost healed when antibiotic therapy was tapered. All patients healed with topical antibiotics except patient 7 who required lamellar keratectomy with conjunctival flap for complete healing; examination of the superficial corneal specimen of this patient revealed chronically inflamed connective tissue covered by nonkeratinized epithelium resembling normal corneal epithelium. No organisms were seen in the sections.

The median time from the onset of signs and symptoms to the resolution of the infiltrate and formation of peripheral corneal scarring was 56 days (range, 21-224 days). The median length of follow-up was 5 months (range, 1.5 months to 2.3 years). Best-corrected visual acuities of the patients at the last follow-up visit was better than 20/40 in 4 of the 7 cases.

COMMENT

Postcataract surgical infections typically appear as endophthalmitis rather than wound infections. The incidence of endophthalmitis after cataract surgery was recently reported to be 0.082%, but the incidence of wound infections is unknown.[5-7] When wound infection after cataract surgery occurs, it may be associated with endophthalmitis, but the frequency of this association has not been determined either.[5,6] There have been some studies on endophthalmitis addressing the incidence of associated wound abscess or necrosis, but these cases of endophthalmitis were not necessarily related to cataract surgery. Their reported incidence ranged from 2.4% to 16%.[4,8-10]

In the literature, there are limited data on wound infections after cataract surgery. In a series of 19 eyes with corneoscleral wound infections after cataract surgery, reported by Valenton[1] from the Philippines, the infectious agents included *S epidermidis*, *S pneumoniae*, *Streptococcus viridans*, *Pseudomonas aeruginosa*, *Mycobacterium fortuitum*, *Aspergillus flavus*, and *Candida tropicalis*. Lopez et al[2] reported 3 cases of pneumococcal endophthalmitis after cataract surgery, and 2 of these 3 cases were associated with keratitis involving limbal cataract incision. van Bijsterveld and Klaassen-Broekema[3]

Our Initial Antibiotic Treatment	Steroid Therapy	Time to Resolution of Infiltrate, d	Duration of Follow-up	Final BCVA (Comment)
Fortified vanco qh; fortified tobra qh; IV vanco, 1g, q6h; and IV genta, 75 mg, q8h	1% Pred qid added at presentation day 5	64	1.5 mo	20/20
Fortified cefa qh; fortified tobra qh	. . .	56	2.3 y	20/50 (PCO)
Ofb q30min; oral cipro, 500 mg, bid	1% Pred q3h	21	2 mo	20/25
Fortified cefa qh; fortified tobra qh (changed to fortified vanco after culture result); oral levoflo, 500 mg, qd	0.5% Loteprednol tid added at presentation day 30	39	9 mo	20/30
Fortified vanco qh; fortified tobra qh; and oral levoflo, 500 mg, bid	1% Pred q2h	224	11 mo	20/20
Fortified vanco qh; fortified tobra qh; and oral levoflo, 500 mg, qd	1% Pred qid	60	5 mo	20/400 (PCO, membrane on IOL)
Fortified cefa qh (changed to fortified vanco after culture result); fortified tobra qh (discontinued after culture result); and oral levoflo, 500 mg, qd	. . .	108	4 mo	20/60 (cornea guttata)

©2001 American Medical Association. All rights reserved.
Downloaded From: https://jamanetwork.com/ on 03/15/2022

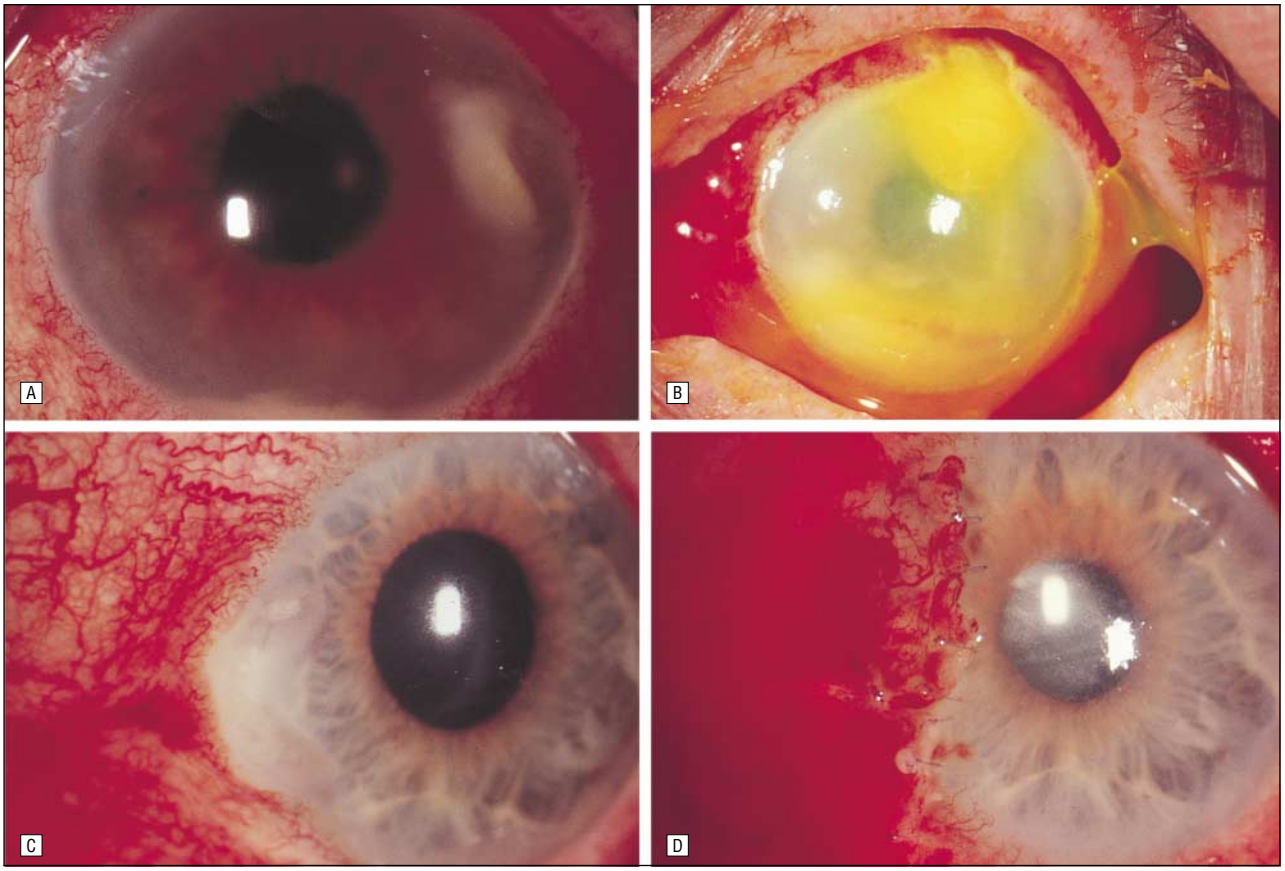

A, Case 4, left eye. Slitlamp view of the conjunctiva shows that it is diffusely hyperemic. A 2.6×3.7-mm infiltrate is seen temporally in the clear corneal phacoemulsification wound. The whole cornea is slightly edematous. There is a 1-mm hypopyon in the anterior chamber. B, Case 6, right eye. Slitlamp view shows the scleral extension of the corneal wound abscess and associated endophthalmitis. A 5.0×5.3-mm corneoscleral abscess superiorly with fibrin and a 2.3-mm hypopyon in the anterior chamber are seen. Note plugged meibomian glands and eyelid telangiectasias due to blepharitis. C, Case 7, left eye. Slitlamp view of the left eye before lamellar keratectomy and conjunctival flap. A 2.0×4.0-mm infiltrate is seen temporally in the clear corneal phacoemulsification wound. D, Slitlamp view of the same eye (see Figure C) after the patient underewent lamellar keratectomy and conjunctival flap surgery.

Table 2. Susceptibility of Cultured Organisms to Antibiotics*

Case No.	Microorganism	Clinda	Cipro	Nafci	TMP/SMX	Tobra	Oflo	Cefa	Erythro	Pen	Tetra	Vanco	Baci	Oxacil
3	*Streptococcus epidermidis*	R	R	R	S	R	R	R	R	R	S	S	S	. . .
4	*Streptococcus pneumoniae*	. . .	S	. . .	. . .	. . .	S	S	S	. . .	. . .	S	S	S
6	MRSA	R	R	. . .	S	R	R	R	R	R	S	S	S	R
7	MRSA	R	R	. . .	S	R	R	R	R	R	S	S	S	R

*Clinda indicates clindamycin; Cipro, ciprofloxacin; Nafci, nafcillin; TMP/SMX, trimethoprim-sulfamethoxazole; Tobra, tobramycin, Oflo, ofloxacin; Cefa, cefazolin; Erythro, erythromycin; Pen, penicillin; Tetra, tetracycline; Vanco, vancomycin; Baci, bacitracin; Oxacil, oxacillin; R, resistant; S, sensitive; ellipses, not applicable; and MRSA, methicillin-resistant *Staphylococcus aureus*.

reported a lacrimal conjunctivitis associated with pneumococcal keratitis at the limbal cataract incision. All organisms recovered in our cases were gram-positive bacteria. Methicillin-resistant *S aureus* was seen in 2 of the 4 culture-proven cases. Other organisms in our study were *S epidermidis* and *S pneumoniae*.

The sources of microorganisms in clear corneal wound infections are unknown but may be similar to those of endophthalmitis. The primary sources of most organisms in infectious endophthalmitis are the patient's own eyelids and conjunctiva that routinely harbor coagulase-negative staphylococci, *S aureus*, *Propionibacterium acnes*, and *Streptococcus* species. Less common, but potentially important, causes of endophthalmitis are associated with contaminated instruments, lenses, or irrigating solutions, respiratory flora of the operating room personnel, and major breaks in sterile techniques.[11,12] In our cases, all of the cataract surgeons denied a break in the sterile technique with their patient.

Some of the proposed risk factors for postoperative endophthalmitis are posterior capsule rupture (loss of anatomical barrier, increased surgical time, and the introduction of multiple instruments to the eye), diabetes mellitus, deficits in immune system, preoperative external ocular infections, eyelid abnormalities, chronic dry eye syndrome, and oral and/or topical steroid use.[8,9,13,14] The

©2001 American Medical Association. All rights reserved.
Downloaded From: https://jamanetwork.com/ on 03/15/2022

use of topical steroids is a risk factor also for developing infectious corneal ulcers.[10,15] In the study with corneoscleral wound infections after cataract surgery by Valenton,[1] predisposing factors were obstructed nasolacrimal duct, airborne contamination of the wound by fungal spores, and defective sterilization of instruments. We could not identify any of these factors except the use of steroids 4 times a day for postoperative iritis without antibiotic coverage before referral in 1 of our patients. In this case, topical steroid use may have predisposed to the late-onset wound infection. However, the anterior chamber reaction may have also been secondary to an unrecognized early wound infection before referral.

The Valenton study also noted that the onset of symptoms generally occurred 1 to 2 weeks after surgery in the staphylococcus, pneumococcus, streptococcus, and pseudomonas infections.[1] In our study, the onset of symptoms ranged from 4 to 60 days after surgery, with a median onset of 10 days.

Rarity of wound infection after cataract surgery might be credited to many factors that render the conjunctival sac relatively sterile such as blinking, tear flow, antimicrobial substances like lysosyme, lactoferrin, β-lysin, and the complement system.[16] We have not seen similar wound infections after large-incision extracapsular cataract surgery. The question arises as to whether a clear corneal incision might be more prone to infection than a corneoscleral incision because of lack of vessels in the cornea, greater contamination, or trauma to the small incision by the tightly fitting phacoemulsification probe, or changes in perioperative antibiotics associated with small incisions and topical anesthesia.

The role of perioperative antibiotics in the prevention of wound infections is unknown. Our case series shows that the microorganism recovered was sensitive to the perioperative prophylactic antibiotic (ciprofloxacin) used in 1 of the 4 culture-proven cases; however, the infection still occurred in this case. However, in the other 3 cases, the microorganisms recovered were not susceptible to the perioperative prophylactic antibiotics (fluoroquinolones and tobramycin) used.

The final visual acuity in 4 of our patients was better than 20/40. The limbal location of the corneal infiltrate out of the visual axis is an important reason for the relatively good visual acuity our patients achieved. Our results were not as poor as the results of Valenton[1] who reported a complete loss of the eye in 10 of the 19 cases with corneoscleral wound infection and endophthalmitis. However, hospitalization was necessary in 6 of our 7 patients and additional surgery was indicated in 1 patient.

There are limitations to this small retrospective study. Data are missing in some cases such as culture results of the wound. In addition, potential preoperative risk factors for postoperative infection were not collected systematically.

CONCLUSIONS

Clear corneal wound infection after phacoemulsification is a serious complication of cataract surgery. The keratitis at the wound site may be associated with scleritis and endophthalmitis. Hospital admission of the patient for fortified antibiotic therapy and additional surgery such as lamellar keratectomy and conjunctival flap may be required. Infections are caused by gram-positive organisms. Our data support the use of typical trimethoprim-polymyxin B sulfate and/or bacitracin for perioperative antibiotic prophylaxis.

Accepted for publication August 1, 2001.

Presented as a poster at the American Society of Cataract and Refractive Surgery and the American Society of Ophthalmic Administrators Symposium on Cataract, Intraocular Lens, and Refractive Surgery, San Diego, Calif, April 28-May 2, 2001.

Corresponding author and reprints: Elisabeth J. Cohen, MD, Cornea Service, Wills Eye Hospital, 900 Walnut St, Philadelphia, PA 19107-5598 (e-mail: ejcohen@hslc.org).

REFERENCES

1. Valenton M. Wound infection after cataract surgery. *Jpn J Ophthalmol.* 1996; 40:447-455.
2. Lopez PF, Beldavs RA, al-Ghamdi S, et al. Pneumococcal endophthalmitis associated with nasolacrimal obstruction. *Am J Ophthalmol.* 1993;116:56-62.
3. van Bijsterveld OP, Klaassen-Broekema N. Lacrimal conjunctivitis. *Bull Soc Belge Ophtalmol.* 1990;238:61-70.
4. Maxwell DP Jr, Diamond JG, May DR. Surgical wound defects associated with endophthalmitis. *Ophthalmic Surg.* 1994;25:157-161.
5. Liesegang TJ. Perioperative antibiotic prophylaxis in cataract surgery [review]. *Cornea.* 1999;18:383-402.
6. Liesegang TJ. Prophylactic antibiotics in cataract operations [review]. *Mayo Clin Proc.* 1997;72:149-159.
7. Aaberg TM Jr, Flynn HW Jr, Schiffman J, Newton J. Nosocomial acute-onset postoperative endophthalmitis survey: a 10-year review of incidence and outcomes. *Ophthalmology.* 1998;105:1004-1010.
8. Driebe WT Jr, Mandelbaum S, Forster RK, Schwartz LK, Culbertson WW. Pseudophakic endophthalmitis: diagnosis and management. *Ophthalmology.* 1986; 93;442-448.
9. Scott IU, Flynn HW Jr, Feuer W. Endophthalmitis after secondary intraocular lens implantation: a case-control study. *Ophthalmology.* 1995;102:1925-1931.
10. Scott IU, Flynn HW Jr, Feuer W, et al. Endophthalmitis associated with microbial keratitis. *Ophthalmology.* 1996;103:1864-1870.
11. Speaker MG, Milch FA, Shah MK, Eisner W, Kreiswirth BN. Role of external bacterial flora in the pathogenesis of acute postoperative endophthalmitis. *Ophthalmology.* 1991;98:639-649.
12. Starr MB. Prophylactic antibiotics for ophthalmic surgery [review]. *Surv Ophthalmol.* 1983;27:353-373.
13. Kattan HM, Flynn HW Jr, Pflugfelder SC, Robertson C, Forster RK. Nosocomial endophthalmitis survey: current incidence of infection after intraocular surgery. *Ophthalmology.* 1991;98:227-238.
14. Menikoff JA, Speaker MG, Marmor M, Raskin EM. A case-control study of risk factors for postoperative endophthalmitis. *Ophthalmology.* 1991;98:1761-1768.
15. Musch DC, Sugar A, Meyer RF. Demographic and predisposing factors in corneal ulceration. *Arch Ophthalmol.* 1983;101:1545-1548.
16. Selinger DS, Selinger RC, Reed WP. Resistance to infection of the external eye: the role of tears [review]. *Surv Ophthalmol.* 1979;24:33-38.

©2001 American Medical Association. All rights reserved.
Downloaded From: https://jamanetwork.com/ on 03/15/2022