Journal of Clinical Monitoring and Computing
https://doi.org/10.1007/s10877-022-00880-8

REVIEW PAPER

Intraoperative recording of laryngeal adductor reflex and cortical motor evoked potentials during jugular foramen schwannoma surgery: a case report and literature review

İrem İlgezdi-Kaya[1,4,5] · Elif Ilgaz-Aydınlar[2] · Pınar Yalınay-Dikmen[2] · Ramazan Sarı[3] · İlhan Elmacı[3]

Received: 11 March 2022 / Accepted: 8 May 2022
© The Author(s), under exclusive licence to Springer Nature B.V. 2022

Abstract

Purpose Schwannoma, a tumor originating from the peripheral nervous system, may arise from the vagus nerve, although it is not very often. Injury of the vagus nerve by surgical attempts may have consequences that will seriously affect the patient's quality of life. In recent years, continuous monitoring of the laryngeal adductor reflex (LAR) has become a promising methodology for evaluating vagus nerve function intraoperatively. We refer to our experience changing our surgical strategy due to concurrent deterioration in LAR and CoMEPs intraoperatively. We also provide a literature review and summarize the current knowledge of this technique.

Methods The LAR was elicited and recorded by an electromyographic endotracheal tube in a 36-year-old man diagnosed with vagal nerve schwannoma. Subdermal needle electrodes were placed in both cricothyroid (CTHY) muscles for corticobulbar motor evoked potentials (CoMEPs) recording.

Results Recordings of ipsilateral LAR and CTHY CoMEPs were obtained despite preoperative ipsilateral cord vocalis weakness. The surgical strategy was altered after the simultaneous decrease of CTHY CoMEPs and LAR amplitudes, and the surgery was completed with subtotal resection. No additional neurological deficit was observed in the patient except dysphonia, which resolved within a few weeks after the surgery.

Conclusions We conclude that LAR with vagal nerve CoMEPs are two complementary methods and provide reliable information about the functional status of the vagus nerve during surgery.

Keywords Laryngeal adductor reflex · Corticobulbar motor evoked potentials · Vagus · Schwannoma · Neuromonitoring

1 Introduction

Schwannoma, a benign, slow-growing tumor originating from Schwann cells, can arise from any peripheral, autonomic or cranial nerve except the olfactory and optic nerves [1]. Nerve sheath tumors form 8% of primary intracranial tumors and sporadic non-vestibular cranial nerve schwannomas 5–10% of cranial nerve sheath tumors. Non-vestibular schwannomas originate from the trigeminal, lower cranial, fascial and oculomotor nerves, respectively [2]. Lower cranial nerve schwannomas (LCNS) may arise from the intracranial or cervical region. Intracranial LCNS usually expands into the jugular foramen or hypoglossal canal. Jugular foramen schwannomas originating from the IX, X, and XI cranial nerves, constitute 2.9–4% of all intracranial schwannomas and 10–30% of tumors around the jugular foramen region [2]. In a review of 19 articles and two

✉ İrem İlgezdi-Kaya MD
iremilgezdi@yahoo.com

1 Istanbul Medical Faculty, Department of Neurology and Neurophysiology, Istanbul University, Istanbul, Turkey

2 Department of Neurology, Acıbadem Maslak Hospital, Istanbul, Turkey

3 Department of Neurochirurgie, Acıbadem Maslak Hospital, Istanbul, Turkey

4 Department of Neurology and Neurophysiology, Istanbul University Istanbul Medicine Faculty, Istanbul, Turkey

5 EEG-EMG unit, Topkapi Mahallesi Turgut Ozal Millet Caddesi Istanbul Universitesi Istanbul Tip Fakultesi Norolojik, Bilimler Binasi Kat:1, Istanbul, Turkey

Published online: 28 June 2022

hundred four patients, jugular foramen schwannomas originated from the glossopharyngeal nerve, vagal nerve, and accessory nerve in 23.6%, 13%, and 5.5% of cases, respectively [3].

The risk of postoperative neurological complication is high in the posterior fossa and brainstem lesions, depending on lesion location and size [4]. Due to the changes in surgical approaches in recent years, preserving neurological functions has become more priority than the complete resection of the tumor, emphasizing the importance of intraoperative neurophysiological monitoring (IONM) [4]. Depending on the surgical location and extent of surgery, monitoring appropriate parameters and interpreting signal abnormalities are essential to prevent permanent loss of neurological functions. Corticobulbar motor evoked potentials (CoMEPs), direct nerve mapping, and free-running electromyography are commonly used to monitor the cranial nerves and nuclei [5, 6].

In 2017, Sinclair et al. described a new technique to record the laryngeal adductor reflex (LAR) and assess the vagal and recurrent laryngeal nerve function intraoperatively [7]. The laryngeal adductor reflex is a brainstem reflex that protects people from aspiration, in which afferent inputs and efferent outputs are carried by two different branches, laryngeal nerve (RLN), respectively.

The afferent arm of the LAR consists of the internal branch of the SLN (iSLN) by supraglottic and glottic stimulation and the RLN by inferior glottic and subglottic stimulation. The efferent arm of the LAR is provided mainly by the RLN, excluding the cricothyroid muscles, which are innervated by the external branch of the SLN (eSLN) [7].

Herein, we describe a patient diagnosed with schwannoma of the cranial nerve X, for whom intraoperative LAR recordings were obtained despite preoperative ipsilateral cord vocalis weakness. We refer to our experience of modifying our surgical strategy due to simultaneous changes in LAR and CoMEPs intraoperatively. We also provide a literature review to collect and summarize this methodology's present state of knowledge.

2 Case report

A 36-year-old man presented with progressive hearing loss in the right ear, minor weakness of the tongue and numbness, difficulty swallowing, and hoarseness for the last few months. His audiological and neurological examination revealed a total hearing loss in the right ear, right palatal, and vocal cord paralysis and a slight right deviation of the genioglossus muscle. His Romberg test was positive, and the tandem walk was impaired.

Magnetic resonance imaging (MRI) showed a heterogeneous enhancing tumor mass with lobulated contours filling the cerebellopontine angle cistern on the right, extending from the jugular foramen to the C2 level outside of the head (Fig. 1).

After induction of general anesthesia, the patient was intubated with an electromyographic endotracheal tube (NIM™ EMG Endotracheal Tube Medtronic). The location of the tube and the position of the electrodes were checked with a video laryngoscope. twisted pair subdermal needle electrodes (150 cm length-coated) were placed at muscles innervated by the lower cranial nerves, upper and lower extremities. Corkscrew electrodes were located at stimulating montage C3/Cz, C4/Cz, C1-C2 (International 10–20 electroencephalography system). For continuous LAR monitoring, a single stimulus (1 ms duration, bandwidth 1.5–1000 Hz) with intensity up to 4mA was alternately applied to the right and left cord vocalis. Responses obtained from the contralateral side of the stimulation were averaged to minimize stimulus artifact. Continuous CoMEPs monitoring was done by a train of three-four voltage stimuli with an ISI of 2.5 ms, a stimulus duration of 0.5 ms, and intensity of 116 V, followed by a single stimulus with the same intensity and stimulus duration. This was recorded by subdermal needle electrodes placed in the target muscles and endotracheal tube. Intermittent nerve mapping with a bipolar stimulator was used to identify any neural structure.

LAR was obtained only on the patient's right side, who was operated on for a same-sided giant mass. The onset latency of the right LAR was 31.13 ms. Right-sided cord

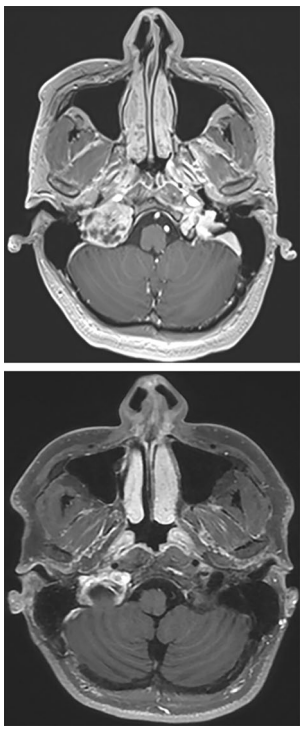

Fig. 1 Preoperative (a) and postoperative (b) gadolinium-enhanced T1 weighted axial MRI images of a vagus schwannoma

vocalis stimulation did not elicit any LAR on the left. We could not reproduce reliable vagal CoMEPs potentials on endotracheal tube recording on both sides. Still, both cricothyroid (CTHY) CoMEPs and other lower cranial CoMEPs were recordable.

At the pontocerebellar angle, a hard encapsulated schwannoma was attached to the brainstem and closely adjacent to the lower cranial nerves. While the tumor capsule was cut, right CTHY CoMEPs' amplitude decreased by 60%, and right LAR's amplitude by 25% simultaneously. Concurrently, cardiac arrhythmia developed, and right LAR gradually almost vanished. The surgeon paused, irrigated the surgical area, and decided to leave a small portion of the mass adjacent to the glossopharyngeal nerve at the jugular foramen entrance. At closing, R LAR amplitude was 26.63 µV, and CTHY CoMEPs amplitude has returned to baseline (Fig. 2).

A temporary dysphonia appeared postoperatively, which has resolved one month later. On first and sixth month follow up, fiberoptic endoscopic evaluation of swallowing revealed right cord median paralysis and a laryngopharyngeal sensory deficit, which was also detected preoperatively. Biopsy results were consistent with schwannoma.

3 Discussion

The LAR is an involuntary reflex that protects the airway from unwanted materials. Monitoring the RLN, SLN, and the vagus nerve is valuable in neck endocrine, cervical spine, and posterior fossa surgeries, which may risk lower cranial nerve damage [8, 9]. Intermittent direct stimulation of the vagus or RLN with a handheld probe is one of the techniques of intraoperative nerve monitoring but does not provide information about surgical integrity between stimulations. However, this method can be used for intraoperative nerve mapping. In contrast, continuous intraoperative nerve monitoring of the LAR can demonstrate potentially impending nerve damage in real-time and provide to alert the surgeon before RLN damage occurs. Sinclair et al. compared intermittent and continuous LAR monitoring in neck endocrine surgeries, and they suggested that continuous LAR monitoring is superior in preventing postoperative transient vocal fold paralysis and paresis over intermittent IONM alone [10]. In 2017, Sinclair et al. introduced a non-invasive and easy technique to record the LAR that could be elicited with endotracheal tube-based electrodes under general anesthesia to evaluate the integrity of the laryngeal and vagus nerves [7].

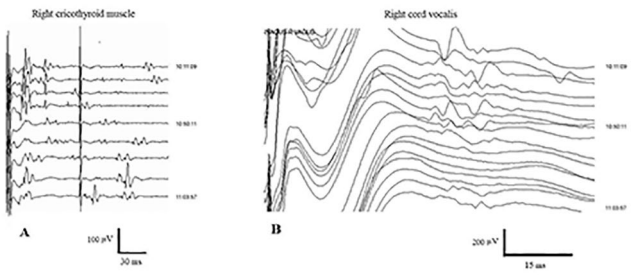

Fig. 2 Decrements of right cricothyroid CoMEPs (baseline peak to peak amplitude of 110.89 µV and latency of 13.30 ms)(a) and right LAR (baseline peak to peak amplitude of 238,66 µV and onset latency of 31.13 ms) (b), which correlates with surgical maneuvers

The afferent pathway of the LAR starts mainly from the supraglottic mucosa. It travels via the SLN to the brainstem, synapses in the solitary tract nucleus and nucleus ambiguous [7]. Post-synaptic efferent fibers travel along the recurrent laryngeal nerve and terminate the cord vocalis [11].

Previous studies have shown that LAR contains an ipsilateral (iR1) and contralateral short-latency response (cR1) and an ipsilateral (iR2) and contralateral (cR2) longer latency response originating from the larynx adductor muscles, and bilateral vocal cord adduction [11, 12].

The mean onset latency of the LAR's right and left R1 components elicited by an endotracheal tube was measured as 22.4 ms and 22.2 ms, respectively, in anesthetized patients [7]. In another study, where hooked-wire electrodes were used for stimulation and recording, the onset latencies were longer, between 30 and 47.5 ms, suggesting the R2 component of LAR. Their stimulation parameters were a train of 3–5 stimuli, 500 ms duration, ISI of 2–4 ms, and intensity < 35 mA. They also observed that the left LAR latency was longer than the right and explained it with a winding route of the left recurrent laryngeal nerve, which crosses the arterial ligament under the aortic arch [9].

In our patient, the onset latency of the right LAR, most probably the R2 component of the reflex, was 31,13 ms. These responses were evoked by stimulating the reflex's left-sided afferent fibers (iSLN), whereas right-sided RLN served as efferent fibers.

Nevertheless, considering the tumor size, it is also possible that the LAR latency is prolonged due to the compressing effect of the large mass causing a slowing of the conduction velocity, and this response may be the R1 component of the reflex. If this is the LAR's R2 component, we assume that the stimulus artifact has superposed the R1 component.

On the other hand, we could not record the LAR on the left side. This could be explained that the mass may have a compressing effect on the right iSLN. In fact, a laryngopharyngeal sensory deficit was detected in the pre-and postoperative evaluations, suggesting that the tumor affected the sensory pathways.

The recordability of the right CTHY CoMEPs reveals that there are still well-functioning fibers of the superior laryngeal nerve and its external branch.

Obtaining CoMEPs from the endotracheal tube is a more practical but not always efficient method compared to the more invasive needle electrodes. In their series where Ichino T et al. used the endotracheal tube, they recorded reliable vagal CoMEPs only in 60% of patients, concluding malrotation may be the main reason for failure [13]. Another technical challenge is that endotracheal tube electrodes can also record far-field muscle activity defined as the contribution of muscles other than the muscle of interest [12].

Ulkatan et al. have made some comments regarding the acquisition of LAR with hook-wire electrodes. Firstly, they suggested that the absence of R1 response, which had shorter latency in pediatric patients than adults, maybe due to a superposing stimulus artifact. They stated that although the primary muscle mediating the LAR is the lateral cricoarytenoid muscle, it may be challenging to place the hook-wire electrodes on the correct muscles due to the proximity of the laryngeal muscles. They also suggested that hook wire electrodes may limit our evaluation of LAR amplitude. They also noted that stimulation of the laryngeal mucosa was specific enough to activate only the adductor laryngeal muscles [14].

Although LAR is classically obtained by stimulation of the glottic and supraglottic mucosa, specific subsites of the laryngeal mucosa reveal LAR better, regardless of their reflex elicitation characteristics. Sinclair et al. reviewed the ability of different glottic and supraglottic subsites to elicit the reflex and mapped sensory receptor density in these regions. In this study, a modified bipolar hand-held stimulating probe was used to stimulate the laryngeal subsites (epiglottic tip, membranous vocal fold, midventricular vocal fold, posterior supraglottis, epiglottic petiole) of 10 patients undergoing head and neck surgery under general anesthesia. LAR was recorded by observation of vocal fold adduction, electrodes embedded in the endotracheal tube, and bilateral lateral cricoarytenoid hook wire electrodes. They showed that the most crucial area generating the bilateral R1 response was the posterior supraglottis, followed by the epiglottic tip and vestibular fold tip and midvestibular fold. Moreover, they demonstrated that high-intensity stimulation made the unilateral response of ventricular fold and epiglottic tip to bilateral and membranous vocal folds could not produce ipsi- or bilateral LAR at any stimulation intensity. They suggested that the appearance of iR1 without cR1 responses despite having the same sensory receptors and afferent reflex arcs indicates that a central control mechanism exists to prevent activation of the contralateral pathway. They hypothetically explained it by central summation of afferent responses on the interneuron at the brainstem level. This model proposed that in regions with high sensory receptor density, enough afferent axons were activated to depolarize the interneuron and initiate the cR1 response. In contrast, areas with less afferent fiber required more intensive stimuli to elicit the cR1 response on the interneuron. Thus, cR1 cannot be obtained in these regions until the stimulus intensity is high enough, while iR1 can occur. Moreover, based on this hypothesis, they explained that previous studies in awake humans did not observe cR1 responses with direct iSLN stimulation with hook-wire electrodes or air puff sensory testing by a relatively weak stimulus [15].

The combined use of LAR and cranial nerve CoMEPs may provide more information on the extent of damage caused by the surgical maneuver. If the afferent branch of the LAR is injured, it is expected that the recording at the contralateral side will be lost [9], while the ipsilateral LAR remains. In our case, the right-sided LAR was lost while cutting the tumor capsule, accompanied by a marked amplitude reduction of the right CTHY CoMEPs and cardiac rhythm changes indicating that the surgical maneuver injured the motor fibers of the right RLN and some autonomic fibers. These neurophysiological decrements enabled the surgeon to change the operative strategy and possibly prevent severe vagus nerve damage.

Similarly, Montes et al. suggested combining LAR with vocal muscle MEPs in lower brainstem surgeries. They reported a 62-year-old patient who underwent a left vestibular schwannoma operation in which LAR, Blink reflex (BR), and CoMEPs changes were interpreted together. They recorded contralateral R1 and R2 responses from the right and left electrodes embedded in the endotracheal tube. During dissection of the tumor, hemodynamic changes were accompanied by a marked decrease of the let BR, which was restored quickly after atropine administration. Another surgical attempt led to significant alteration of left LAR cR1, right LAR cR1, and cR2, the left vocal CoMEPs amplitudes with neurotonic discharges in the left X cranial nerve on free-run EMG. LAR and CoMEPs returned to baseline after atropine was applied. Postoperatively, the patient presented with worsening left facial paralysis and dysphagia, which required a soft diet and gradually improved within 48 h [16].

Although there is no definite warning criterion for the neuromonitoring of the LAR reflex, some studies have some recommendations. In a study conducted by Sinclair et al. where 134 at-risk nerves from 100 neck endocrine surgeries were included, warning criteria for LAR monitoring were defined. They showed that a 60% decrease in LAR amplitude relative to the baseline or absolute closing amplitude < 100 μV was associated with laryngeal and vocal fold paralysis [12]. They underlined that LAR latency might fail to predict nerve damage because the LAR reflex arc is

driven by different sensory and motor axon fibers with varying conduction velocities. Also, slight movements of the endotracheal tube and nearby mucosa during surgical tissue manipulation may cause latency variability [12]. They suggested that baseline LAR parameters should be taken before neck incision or tissue manipulation. They highlighted that if the LAR opening amplitude is < 150 mV, alternative monitoring techniques should be considered due to the unreliability of the LAR response. An amplitude between 150 and 200 mV is still not reliable enough and should be supported with another technique such as direct nerve stimulation. An amplitude decline of > 50% from the baseline may be a reason to alarm the surgical team and release tissue to avoid any nerve damage. On the other hand, preservation of the LAR predicts a good outcome for lower brainstem surgery [9]. Most probably, the LAR seems to be earlier affected than the compound muscle action potential (CMAP) of the RLN due to the chance that sensory fibers are easier stretch-injured. It is recommended to elicit vagal CMAP and palpate twitching in the posterior cricoarytenoid area if LAR does not return to baseline after release [12].

It has also been reported that LAR loss may not be correlated with any postoperative vocal cord paralysis. Satomaa et al. monitored the LAR response in a 12-year-old patient with a fourth ventricle astrocytoma. They elicited LAR response by stimulating left and right laryngeal mucosa with surface electrodes embedded in the endotracheal tube, recorded by hook wire electrodes placed in the thyroarytenoideus muscles. They have observed that a loss of a unilateral LAR response did not lead to any postoperative vocal cord function impairment and concluded that LAR loss has no impact on postoperative functions [17]. In response to this letter, Pescador et al. have explained that the reasons for the undetectable relationship between LAR response and the postoperative laryngeal deficit may be related to a stimulation fault, possible asymmetrical placement of the electrodes, dislodgement of the recording electrode, the absence of recording of baseline ipsilateral R1 response, and the postoperative evaluation was performed by only a subjective voice evaluation rather than endoscopic laryngeal examination. [18].

Our patient's surgical incision threatening the vagus nerve led to an almost total loss of the ipsilateral LAR and an amplitude decline of more than 50% of the ipsilateral CTHY CoMEPs. At closing, the ipsilateral CTHY CoMEPs have returned to baseline values, whereas the LAR amplitude was only 26.63 µV which was too small for a reliable neuromonitoring. Considering that the LAR is always bilateral, this value might also be a far-field recording of the left LAR. Excessive stretching of the nerve root and its peripheral part, ischemia, compression, or injury to the corticospinal tract, may cause amplitude reduction in motor evoked potentials [19]. Previous studies showed that a less than 50% reduction in amplitude in facial CoMEPs at the end of cerebellopontine and skull base surgeries was considered a good prognostic sign [20–22]. In our patient, although LAR remained with a very small amplitude at closing, the preservation after a temporary deterioration of CTHY CoMEPs led us to conclude that the vagal nerve's axons probably stayed intact. Indeed the patient has presented with transient dysphonia after surgery but has recovered to his preoperative status after a while.

A similar situation was observed with another brainstem reflex, the Blink reflex (BR), where deterioration of the reflex helped as an early warning sign and led to a change in the surgical approach. The BR also was sensitive, foreseeing early postoperative neurological weakness. On the other hand, facial CoMEPs were superior in accurately predicting long-term facial nerve functions [23].

The preservation of the LAR R2 component during the surgery in adults is rare. In contrast, it is recordable in pediatric patients until the end of the operation under target-controlled TIVA infusion. By recording the R2 component, the function of the vagus nerve, medulla oblongata, and the reflex's polysynaptic brainstem pathway are monitored. It is presumed that the preservation of R2 could potentially be used as an indicator of the patient's wakefulness after anesthesia. Likely, the R2 part also indicates the integrity of the reticular activator system, which is located in the brainstem and regulates the patient's arousal [14].

Although the cR1 response is supported by central facilitation, it has been reported that it can be suppressed depending on the dose of anesthesia [11]. Sinclair et al. stated that both cR1 and cR2 LAR components could be taken under total intravenous anesthesia (TIVA) in a case series of 21 patients who had undergone various neck surgeries. While cR1 was recorded on both right and left sides throughout the surgery, the cR2 response was noted in 14 patients at the beginning of the operation and has vanished in 9 patients unrelated to any surgical maneuver. In this study, mean cR1 or R1 latency was 22.5 + 2.5 milliseconds (ms) on the left and 23.4 + 3.3 ms on the right. Mean cR2 or R2 latency was 59.8 + 4.9 ms on the left and 61.8 + 7.9 ms on the right. They also emphasized that postoperative evaluation was performed by only a subjective voice evaluation rather than endoscopic laryngeal examination. Inhalational anesthetic agents can eliminate all reflex components, and topical laryngeal anesthesia can significantly reduce the response amplitude [24]. In this case, anesthesia was stable, and neurophysiological changes were strictly related to surgical maneuvers.

4 Conclusions

We are still in the early phases of how LAR and other brainstem reflexes work during surgery, and we do not know precisely what scenarios might arise. The interpretation of intraoperative changes of these reflexes is challenging if the surgery is in the brainstem, where the systems have bilateral connections. On the other hand, understanding baseline recording parameters and predicting the impact of intraoperative LAR and CoMEPs decrements is relatively more uncomplicated in schwannoma surgeries where the fiber structure is fully known. We conclude that LAR with vagal nerve CoMEPs are two complementary methods and provide reliable information about the functional status of the peripheral nerves during surgery.

Acknowledgements We thank Sedat Ulkatan for his valuable comments on earlier drafts of this paper.

Funding The authors declare that no funds, grants, or other support were received during the preparation of this manuscript.

Declarations

Informed consent Written informed consent was obtained from the patient.

Conflict of interest None.

References

1. Behuria S, Rout TK, Pattanayak S. Diagnosis and management of schwannomas originating from the cervical vagus nerve. Ann R Coll Surg Eng. 2015;97:92–7.
2. Suarez C, Lopez F, Mendenhall WM, et al. Trends in the Management of Non-Vestibular Skull Base and Intracranial Schwannomas. Cancer Manag Res. 2021;13:463–78.
3. Bakar B. The jugular foramen schwannomas: review of the large surgical series. J Korean Neurosurg Soc. 2008;44:285–94.
4. Tellez MJ, Miralleve-Pescador A, Siedel K, et al. Neurophysiological monitoring of the laryngeal adductor reflex during cerebellar-pontine angle and brainstem surgery. Clin Neurophysiol. 2021;132:622–31.
5. Deletis V, Fernández-Conejero I. Intraoperative Monitoring and Mapping of the Functional Integrity of the Brainstem. J Clin Neurol. 2016;12:262–73.
6. Romstöck J, Strauss C, Fahlbusch R. Continuous electromyography monitoring of motor cranial nerves during cerebellopontine angle surgery. J Neurosurg. 2000;93:586–93.
7. Sinclair CF, Tellez MJ, Tapia OR, et al. A novel methodology for assessing laryngeal and vagus nerve integrity in patients under general anesthesia. Clin Neurophysiol. 2017;128:1399–405.
8. Sinclair CF, Tellez MJ, Sanchez Roldan MA, et al. Intraoperative Mapping and Monitoring of Sensory Vagal Fibers During Vagal Schwannoma Resection. Laryngoscope. 2019;129:434–6.
9. Costa P, Gaglini PP, Tavormina P, et al. A method for intraoperative recording of the laryngeal adductor reflex during lower brainstem surgery in children. Clin Neurophysiol. 2018;129:2497–8.
10. Sinclair CF, Téllez MJ, Ulkatan S. Continuous Laryngeal Adductor Reflex Versus Intermittent Nerve Monitoring in Neck Endocrine Surgery. Laryngoscope. 2021;131:230–6.
11. Sasaki CT, Jassin B, Kim YH, et al. Central facilitation of the glottic closure reflex in humans. Ann Otol Rhinol Laryngol. 2003;112:293–7.
12. Sinclair CF, Tellez MJ, Ulkatan S. Noninvasive, tube-based, continuous vagal nerve monitoring using the laryngeal adductor reflex: feasibility study of 134 nerves at risk. Head Neck. 2018;40:2498–506.
13. Ichino T, Tanaka S, Tanaka R, et al. Transcranial motor-evoked potentials of laryngeal muscles for intraoperative neuromonitoring of the vagus nerve during thyroid surgery. J Anesth. 2019;33:221–9.
14. Ulkatan S, Tellez MJ, Sinclair C. Laryngeal adductor reflex and future projections for brainstem monitoring. Reply to a method for intraoperative recording of the laryngeal adductor reflex during lower brainstem surgery in children. Clin Neurophysiol. 2018;129:2499–500.
15. Sinclair CF, Tellez MJ, Ulkatan S. Human laryngeal sensory receptor mapping illuminates the mechanisms of laryngeal adductor reflex control. Laryngoscope. 2018;128:365–70.
16. Montes V, Elarjani T, Khairy S, et al. Valuableness of introduction of laryngeal adductor reflex intraoperative neuromonitoring technique in lower brainstem lesion. Surg Neurol Int. 2020;11:425.
17. Satomaa AL, Vanttinen S, Mattila H. The intraoperative laryngeal adductor reflex (LAR) in brainstem tumor removal: A case of unilateral loss of LAR signal. Clin Neurophysiol. 2019;130:1253–5.
18. Mirallave-Pescador A, Sanchez Roldan MA, Tellez MJ, et al. Unforeseen clinical outcome for laryngeal adductor reflex loss during intraaxial brainstem surgery. Clin Neurophysiol. 2019;130:2001–2.
19. MacDonald DB. Intraoperative motor evoked potential monitoring: overview and update. J Clin Monit Comput. 2006;20:347–77.
20. Acioly MA, Liebsch M, Carvalho CH, et al. Transcranial electrocortical stimulation to monitor the facial nerve motor function during cerebellopontine angle surgery. Neurosurgery. 2010;66:354–61.
21. Akagami R, Dong CC, Westerberg BD. Localized transcranial electrical motor evoked potentials for monitoring cranial nerves in cranial base surgery. Neurosurgery. 2005;57:78–85.
22. Dong CC, MacDonald DB, Akagami R, et al. Intraoperative facial motor evoked potential monitoring with transcranial electrical stimulation during skull base surgery. Clin Neurophysiol. 2005;116:588–96.
23. Aydınlar EI, Kocak M, Soykam HO, et al (2020) Intraoperative Neuromonitoring of Blink Reflex During Posterior Fossa Surgeries and its Correlation With Clinical Outcome. J Clin Neurophysiol Sep 28.
24. Sinclair CF, Tellez MJ, Tapia OR, Ulkatan S. Contralateral R1 and R2 Components of the Laryngeal Adductor Reflex in Humans Under General Anesthesia. Laryngoscope. 2017;127:443–8.

Publisher's note Springer Nature remains neutral with regard to jurisdictional claims in published maps and institutional affiliations.