Interactive CardioVascular and Thoracic Surgery 21 (2015) 691–693
doi:10.1093/icvts/ivv226 Advance Access publication 11 August 2015

Cite this article as: Colkesen Y, Baykan O, Dagdelen S, Cayli M. Transcatheter aortic valve implantation in a patient with bicuspid aortic stenosis and a borderline-sized annulus. Interact CardioVasc Thorac Surg 2015;21:691–3.

Transcatheter aortic valve implantation in a patient with bicuspid aortic stenosis and a borderline-sized annulus

Yucel Colkesen[a,*], Oytun Baykan[a], Sinan Dagdelen[b] and Murat Cayli[a]

[a] Department of Cardiology, Adana Numune Training and Research Hospital, Seyhan Adana, Turkey
[b] Department of Cardiology, Acibadem University Faculty of Medicine, Istanbul, Turkey

* Corresponding author. Department of Cardiology, Adana Numune Training and Research Hospital, 01140 Seyhan Adana, Turkey. Tel: +90-5334795944; fax: +90-3223271279; e-mail: kardiyoloji@yahoo.com (Y. Colkesen).

Received 19 May 2015; received in revised form 6 July 2015; accepted 16 July 2015

Abstract

Bicuspid aortic valve (BAV) is currently considered an exclusion criterion for transcatheter aortic valve implantation (TAVI). The risk of adverse aortic events such as incomplete sealing, severe paravalvular regurgitation or dislocation due to elliptic shape and asymmetric calcifications in annulus are higher in TAVI. In this case report, we detailed a case of successful trans-femoral TAVI in a 51-year old male with BAV and its management without in-hospital and 30-day complications. The challenge in this case was the patient's anatomy with a 27-mm annulus for balloon expandable device. The applied strategy was balloon sizing and overdilating the 29-mm stented valve with additional volume that obviated re-ballooning. Trans-femoral TAVI was performed uneventfully under fluoroscopic and transoesophageal echocardiography guidance. A multidetector computed tomography (MDCT) evaluation at 1 month did not show device dislodgement or any other complications. Evidence for evaluation post-TAVI is not sufficient in BAV. We believe patients with BAV should undergo a comprehensive assessment after TAVI including MDCT evaluation.

Keywords: Transcatheter aortic valve implantation • Bicuspid valve • Severe aortic stenosis

INTRODUCTION

Bicuspid aortic valves (BAV) puts patients at an increased risk of adverse aortic events such as device dislocation secondary to progressive annulus dilatation and malfunctioning following transcatheter aortic valve implantation (TAVI) [1]. To overcome the potential risks of post-TAVI particularly in borderline-sized aortic annuli, device oversizing that is associated with optimal clinical outcomes may be taken into account [2]. This could be accomplished either by selecting a larger transcatheter heart valve (THV) device rather than a recommended size or by dilating the device with additional volume. Owing to limited THV sizes, overdilating the THV with balloon in individualized cases with upper limits of annular size appears to be the sole option. We here explain a successful TAVI procedure in a patient with BAV and a borderline-sized annulus and the results of multidetector computed tomography (MDCT) at 1 month postoperatively.

CASE REPORT

We present a 51-year old male with symptomatic BAV stenosis and a history of coronary artery bypass surgery. The patient had left internal mammary artery to left anterior descending artery and saphenous vein graft to obtuse marginal artery. Coronary angiography revealed that grafts were patent and that the right coronary artery was rudimentary. Baseline transthoracic echocardiography reported an aortic valve area of 0.9 cm^2, mean gradient of 41.0 mmHg, mean velocity of 312 cm/s and dimensionless valve index of 0.23. Left ventricular ejection fraction was 64%. Surgical aortic valve replacement was offered because EuroSCORE did not reflect a high risk. The patient rejected surgery. TAVI was suggested as an alternative strategy. But we underlined that BAV is currently considered a contraindication and the procedure could be considered only after a careful examination with transoesophageal echocardiography (TOE), multidetector computed tomography (MDCT) and coronary and peripheral angiography. He accepted the risks and signed an informed consent.

TEE identified fusion of the right and non-coronary cusps (BAV Type 1, R-N, S). A raphe was seen extending from the commissure to the free edge of the under developed conjoint cusps in short axis (Fig. 1A). The diameters of aortic annulus and ascending aorta at sinotubular junction were 27 and 42 mm, respectively. MDCT documented a relatively spheric annulus (Fig. 1B) and a 42-mm ascending aorta. Both TEE and MDCT did not reveal an excessively elliptic aortic annulus. Aortoiliac angiography detected normal lumen and adequate sizes of the iliac and femoral arteries. A 29-mm Edwards SAPIEN XT THV (Edwards Lifesciences, Inc., Irvine, CA, USA) implantation via trans-femoral access was decided upon. A Novaflex (Edwards Lifesciences, Inc.) deployment

© The Author 2015. Published by Oxford University Press on behalf of the European Association for Cardio-Thoracic Surgery. All rights reserved.

Downloaded from https://academic.oup.com/icvts/article/21/5/691/2363294 by guest on 15 March 2022

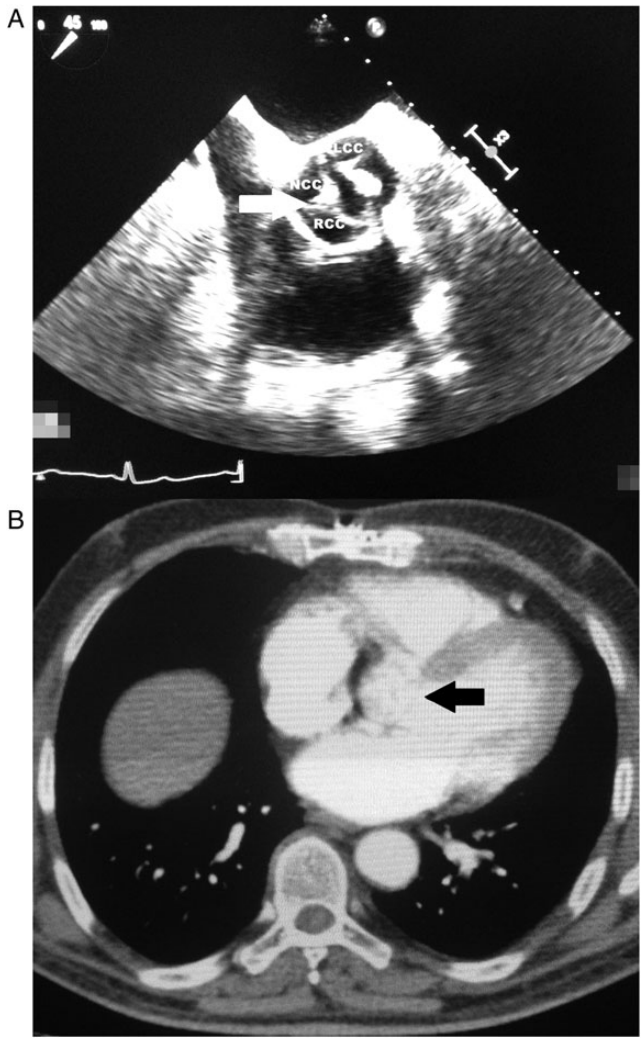

Figure 1: (**A**) TEE at short axis demonstrates a raphe (arrow) between the right and non-coronary cusps. (**B**) Axial MDCT shows spheric annulus (arrow). NCC: non-coronary cusp; LCC: left coronary cusp; RCC: right coronary cusp; MDCT: multidetector computed tomography; TEE: transoesophageal echocardiography.

catheter was inserted through the right common femoral artery. Preimplantation balloon valvuloplasty was done with a 24-mm Amplatzer (St Jude Medical, MN, USA) sizing balloon. Full balloon expansion could be achieved. The patient did not develop significant aortic incompetence after balloon valvuloplasty. To prevent valve migration, additional 4 ml volume that is advised for post-dilatation in a 29-mm valve was added to 33 ml nominal inflation volume before deployment. Valve alignment was done under fluoroscopic and TEE guidance. The position of the implanted valve was optimal and re-ballooning was not required. There was significant haemodynamic improvement with a reduction in mean pressure gradient to 7 mmHg. The valve appeared to open symmetrically with a circular appearance with minimal paravalvular aortic incompetence on TEE (Fig. 2A). A 10% increase in valved stent area (from 660 to 680 mm^2) was achieved (Fig. 2B). No complications were observed during the operation. The patient was discharged on the fifth day of implantation. At 1 month, MDCT exhibited a precise positioning (Fig. 2C) and a circular shape of the stent. No valve embolization, aortic dissection or annular rupture was reported.

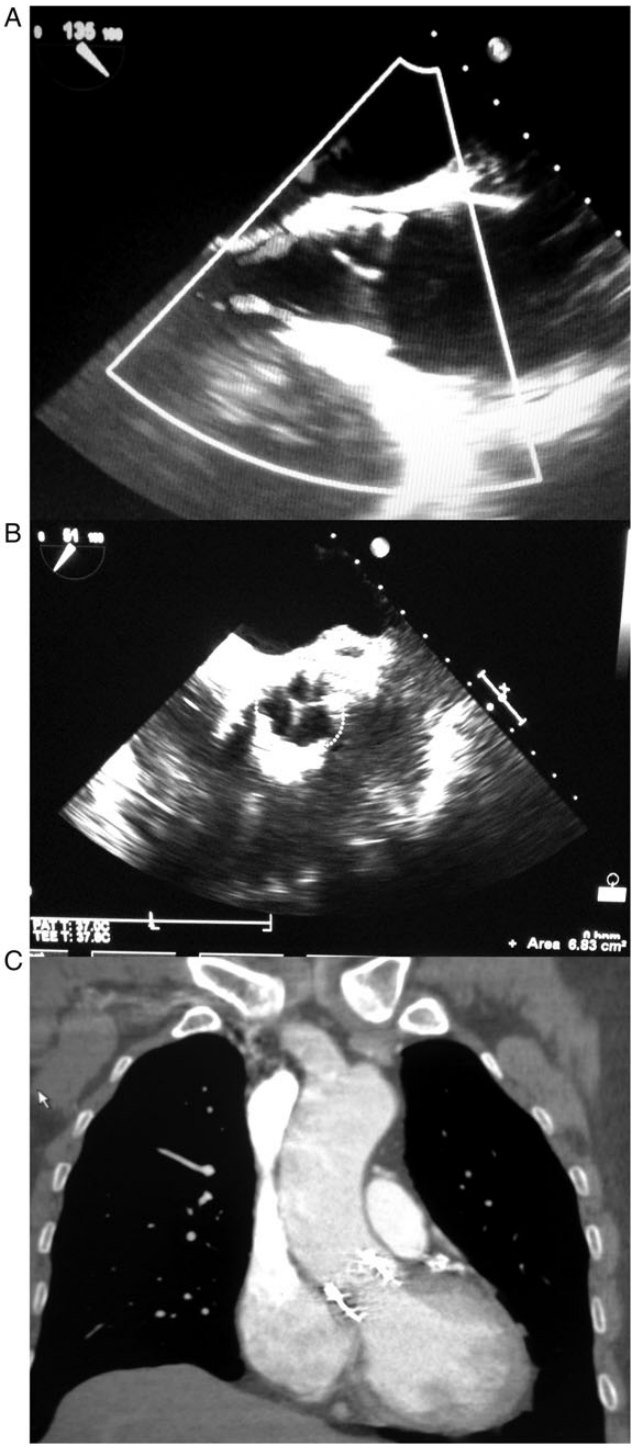

Figure 2: (**A**) TEE demonstrates minimal paravalvular aortic incompetence (long axis) and (**B**) an increased valved stent area (short axis). (**C**) Lateral MDCT image of the aortic root shows the valve position at 1 month. TEE: transoesophageal echocardiography; MDCT: multidetector computed tomography.

DISCUSSION

There is insufficient data in the form of randomized clinical studies to prove the safety or efficacy of TAVI in BAVs. Short- and mid-term follow-up appears uneventful in observational studies that suggest that TAVI is technically feasible, safe and effective [1].

Downloaded from https://academic.oup.com/icvts/article/21/5/691/2363294 by guest on 15 March 2022

Valve durability and long-term (1-year) outcomes in a large number of patients are lacking. BAV is considered a contraindication to TAVI due to increased risk of paravalvular leak, eccentric geometry of the aortic root, potential deformity of the deployed prosthesis and valve migration. Increased probability of incomplete sealing, severe paravalvular regurgitation, dislocation or malpositioning due to elliptic shape and asymmetric calcifications in annulus are possible complications after TAVI. Patients with BAV have higher gradients, larger annulus perimeters and more calcified valves compared with non-BAV. Higher post-procedural gradient and valve under-expansion also depends on the type of valve implanted. Generally, a balloon expandable bioprosthesis forms a round shape after full expansion. However, asymmetrical anatomy of the annulus may increase the risk of uneven expansion of the valve. This, in principle, may cause leaflet deformity, valve dysfunction and stent misdeployment. Paravalvular leak and device migration as a result of valve undersizing may contribute to early complications [3]. Asymmetrical expansion may occur with self-expanding valves in BAV [4]. In general, the device is successfully deployed in BAV cases. Both balloon expandable and self-expanding valves display an oval shape showing that BAV does not limit an efficient sealing. Therefore, post-procedural AR is not significantly different from the non-BAV group [1]. Moreover, oversizing the balloon expandable valve up to 10% may achieve a firm anchorage to the annulus and prevent displacement, migration and the occurrence of moderate or severe aortic regurgitations [2].

A preoperative evaluation of the valve morphology should be done comprehensively by computed tomography, TEE and 3D echocardiography. TAVI should be avoided in BAV with extreme calcifications, extensive asymmetric valves, very elliptic annulus or small distance from leaflets to the coronary ostia. The success rate depends on patient selection; thus, it is very important to exclude those with high risk for device failure. Aortic dissection, progressive aortic root dilatation and rupture need to be considered in the context of TAVI [4]. Follow-up echocardiography and MDCT can precisely assess the function and correct positioning of the prosthesis in relation to the surrounding structures [5].

To improve the clinical outcomes of TAVI in BAV, along with careful patient selection, a personalized approach with optimal degree of overdilating while implanting the device should be taken into consideration.

Conflict of interest: none declared.

REFERENCES

[1] Kochman J, Huczek Z, Scisło P, Dabrowski M, Chmielak Z, Szymański P *et al*. Comparison of one- and 12-month outcomes of transcatheter aortic valve replacement in patients with severely stenotic bicuspid versus tricuspid aortic valves (results from a multicenter registry). Am J Cardiol 2014;114:757–62.

[2] Samim M, Stella PR, Agostoni P, Kluin J, Ramjankhan F, Sieswerda G *et al*. A prospective "oversizing" strategy of the Edwards SAPIEN bioprosthesis: results and impact on aortic regurgitation. J Thorac Cardiovasc Surg 2013;145:398–405.

[3] Mylotte D, Lefevre T, Søndergaard L, Watanabe Y, Modine T, Dvir D *et al*. Transcatheter aortic valve replacement in bicuspid aortic valve disease. J Am Coll Cardiol 2014;64:2330–9.

[4] Himbert D, Pontnau F, Messika-Zeitoun D, Descoutures F, Détaint D, Cueff C *et al*. Feasibility and outcomes of transcatheter aortic valve implantation in high-risk patients with stenotic bicuspid aortic valves. Am J Cardiol 2012;110:877–83.

[5] Delgado V, Tops LF, Schuijf JD, van der Kley F, van de Veire NR, Schalij MJ *et al*. Successful deployment of a transcatheter aortic valve in bicuspid aortic stenosis: role of imaging with multislice computed tomography. Circ Cardiovasc Imaging 2009;2:e12–13.

Downloaded from https://academic.oup.com/icvts/article/21/5/691/2363294 by guest on 15 March 2022